

Received: 01.02.2018

Accepted: 03.09.2018

Published: 31.10.2018

Nurul Farahiyah Abdullah^{1,2}, Shamina Saramoses², Norzi Gazali², Irfan Mohamad¹

Chicken bone in the bronchus masquerading as bronchopneumonia in an asthmatic boy

Kość kurczaka w oskrzeli dająca objawy odoskrzelowego zapalenia płuc u chłopca z astmą

¹ Department of Otorhinolaryngology, Head & Neck Surgery, School of Medical Sciences, Universiti Sains Malaysia Health Campus, 16150 Kota Bharu, Kelantan, Malaysia

² Department of Otorhinolaryngology, Hospital Sultanah Bahiyah, Alor Setar, Malaysia

Correspondence: Dr Nurul Farahiyah Abdullah, Department of Otorhinolaryngology, Head & Neck Surgery, School of Medical Sciences, Universiti Sains Malaysia Health Campus, 16150 Kota Bharu, Kelantan, Malaysia, tel.: +6097676420, fax: +6097676424, e-mail: farahiyahabdullah0105@gmail.com

Abstract

Aim of the study: To emphasise the importance of a thorough history to exclude foreign body inhalation in children presenting with respiratory symptoms. **Case study:** We report a case of a 2-year-old boy with underlying bronchial asthma, who presented with cough and difficulty breathing of two-day duration, with no stridor. He was treated for acute exacerbation of bronchial asthma and bronchopneumonia. However, the symptoms persisted despite treatment. A detailed history revealed a choking episode while eating chicken curry prior admission. Bronchoscopy confirmed the presence of a piece of chicken bone in the left main bronchus, which was removed. The child was in good overall condition after the operation. Chest radiograph showed resolved lung collapse. **Conclusion:** A thorough history to exclude foreign body ingestion is necessary to avoid delayed complications of foreign body aspiration.

Keywords: bronchopneumonia, foreign body inhalation, bronchus

Streszczenie

Cel badania: Podkreślenie znaczenia wywiadu chorobowego dla wykluczenia aspiracji ciała obcego u dzieci z objawami ze strony układu oddechowego. **Opis przypadku:** W pracy przedstawiono przypadek 2-letniego chłopca z astmą oskrzelową, u którego od dwóch dni utrzymywały się kaszel i trudności w oddychaniu bez obecności świstu krtaniowego. Pacjenta poddano leczeniu z powodu ostrego zaostrzenia astmy oskrzelowej i odoskrzelowego zapalenia płuc, jednak nie dało ono oczekiwanych rezultatów. Szczegółowy wywiad chorobowy ujawnił epizod zakrztuszenia potrawą curry z kurczaka przed przyjęciem do szpitala. Bronchoskopia potwierdziła obecność kości kurczaka w lewym głównym oskrzeli, którą następnie usunięto. Stan dziecka po zabiegu oceniono jako dobry. W badaniu radiologicznym klatki piersiowej stwierdzono ustąpienie objawów zapaści płuca. **Wniosek:** Dokładny wywiad w celu wykluczenia obecności ciała obcego jest niezbędny, aby uniknąć powikłań.

Słowa kluczowe: odoskrzelowe zapalenie płuc, aspiracja ciała obcego, oskrzele

INTRODUCTION

Foreign body (FB) inhalation is common in children as they are prone to aspirate foreign material. Such cases require prompt diagnosis and immediate intervention to avoid potentially fatal consequences. Organic FBs are the most common type of inhaled material. In 2000, FB aspiration accounted for more than 17,000 emergency department visits of children younger than 14 years in the United States alone⁽¹⁾. The majority of foreign bodies (91.43%) were organic in nature⁽²⁾. Nuts were the most common form, amounting for 59% of cases⁽³⁾.

FB inhalation manifests mainly as upper airway obstructive symptoms, cough and wheezing. The most common symptoms and findings include cough, dyspnoea, stridor, decreased breath sounds as well as the presence of a radio-opaque FB, air trapping, and atelectasis on chest radiograph⁽⁴⁾.

Suspected FB inhalation requires emergency bronchoscopy and removal. Plain chest radiograph revealed radio-opaque foreign bodies in 23.56% of all patients with FB inhalation⁽⁵⁾.

The purpose of this case report is to emphasise the importance of a thorough history to exclude foreign body inhalation in children presenting with respiratory symptoms.

CASE REPORT

A 2-year-old boy presented with difficulty breathing and cough lasting for 2 days prior to admission. He also had one episode of fever. Otherwise, there was no wheezing, stridor or cyanotic episode. The child was active and as usual. The boy used a nebuliser once in every 2 months since 3 months old. No history of intubation documented.

An initial assessment showed that the child was not tachypneic. No chest recession was observed. Auscultation revealed lung crepitation and prolonged expiration.

Chest radiograph showed mild haziness over the left lower and middle zone (Fig. 1). The child was initially treated as bronchopneumonia with acute exacerbation of bronchial asthma. Intravenous antibiotic was prescribed.

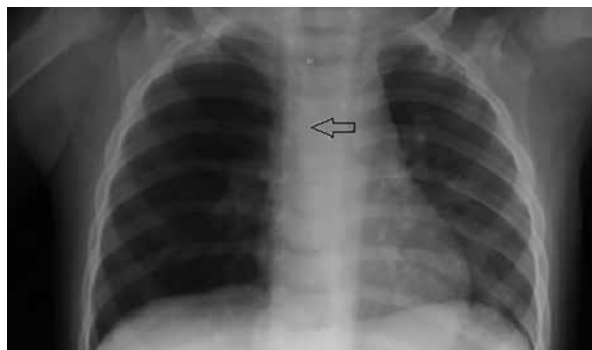


Fig. 1. Initial chest radiograph showed tubular linear opacity in the right main bronchus

However, the cough worsened and chest recession occurred during his hospital stay. On day 3 of admission, the boy became more tachypneic, his condition deteriorated and intubation was needed. Post intubation chest radiograph showed left lung collapse and a vague linear opacity within the left main bronchus (Fig. 2).

Further history revealed a choking episode while eating chicken curry 2 days prior to hospitalisation.

An urgent bronchoscopy was performed and confirmed the presence of a chicken bone in the left main bronchus (Fig. 3). The bone was removed (Fig. 4) and no signs of inflammation or granulation tissue were observed. The supraglottic, glottic, subglottic structures and the rest of the tracheobronchial tree were normal.

After bronchoscopy, the child was monitored in a paediatric intensive care unit. His general condition improved and a follow-up chest radiograph showed that the left lung collapse resolved.

DISCUSSION

Prompt diagnosis of FB inhalation is crucial to avoid respiratory complications and a fatal outcome. Undiagnosed FB inhalation can cause mechanical and chemical reactions, leading to chronic pulmonary infection, bronchiectasis, asthma, lung collapse, lung abscess and bronchial stenosis in long-term impaction of a foreign body. Eliciting history of FB ingestion or inhalation is vital in children with respiratory symptoms.

Late diagnosis of FB inhalation is defined as occurring beyond 3 days between FB aspiration or onset of symptoms and a correct diagnosis. Among 210 cases of late FB aspiration, there were 6 causes of delayed detection, especially in children⁽⁶⁾. The most common reasons of delayed detection include parental negligence (50%), followed by misdiagnosis (19%), normal chest radiograph (14%), lack of typical symptoms and signs (12%), mismanagement (4%) and negative bronchoscopic findings (1%)⁽⁶⁾.

Parental negligence occurs when the child appears asymptomatic after FB aspiration or if the choking episode is not witnessed. In our case, the child appeared

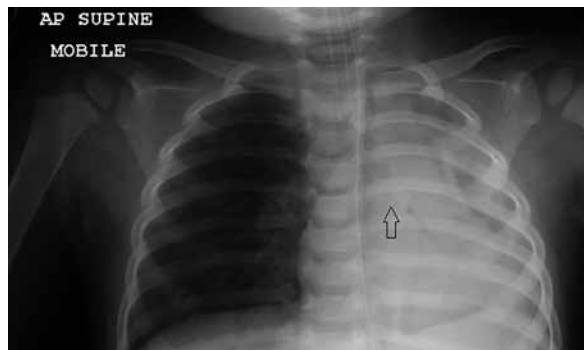

Fig. 2. A repeated chest radiograph shows that the foreign body migrated into the left main bronchus and left lung collapse

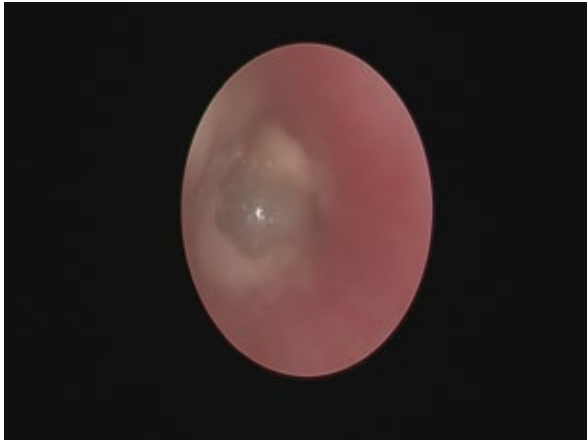

Fig. 3. Fleshy glistening-textured foreign body seen in the left main bronchus

asymptomatic immediately after the incident of choking, with no signs of respiratory distress. Parents will only seek medical treatment when their child develops complications, such as pneumonia, bronchitis or lung collapse. Misdiagnosis may occur in the first phase of acute dyspnoea during aspiration as it can be unnoticed. In such cases, aspiration may be treated as a lung disease. The most common symptoms and signs of FB inhalation are cough, wheezing, and reduced breath sounds, which can be overlooked, especially when the patient already has bronchial asthma.

The presence of cough for a certain period of time, before pneumonia, which is diagnosed as bronchitis, should indicate the probability of FB in the bronchus, especially when pneumonitis followed after and did not resolve on appropriate therapy.

In our case, history of FB ingestion was missed at the initial presentation and the child showed no treatment response. His condition deteriorated and repeated chest radiograph revealed left lung collapse. Retrospective history revealed FB ingestion 2 days prior hospitalisation. The delay in diagnosis was due to the fact that the incident happened when the child stayed at nursery and the caretaker who witnessed the choking episode was not present during admission. The child also had bronchial asthma that misled the physician.

Foreign bodies may be classified as organic and inorganic. Organic types include nuts, seeds, foods and vegetables while inorganic include needles, plastic elements, toys, crayons and dentures. Nuts are the most commonly reported inhaled FBs⁽⁷⁻⁹⁾. There are differences in long-term complications between aspirated organic and inorganic materials⁽¹⁰⁾. No persistent symptoms (such as cough or wheezing) or bronchiectasis are reported following inorganic FB aspiration, whereas organic materials increase the risk of persistent symptoms and bronchiectasis⁽¹⁰⁾. Organic FBs are known to initiate inflammation of the adjacent tissue in the airways. Some cases of inorganic FB inhalation are asymptomatic when the FB does not obstruct the airway. Poukkula et al. reported 2 cases of a denture

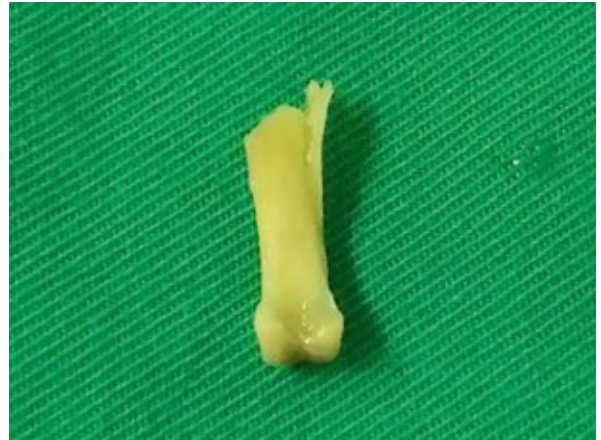

Fig. 4. A removed piece of chicken bone

lodged in the bronchus, in which symptoms developed after 6 years⁽¹¹⁾.

Chest radiograph plays an important role in diagnosing FB inhalation. When there is a suggestive history of FB aspiration or plausible suspicion, chest radiograph is necessary to show the radio-opaque FB. However, negative chest radiography findings do not exclude the diagnosis of FB aspiration. Bronchoscopy should be performed to establish the diagnosis. In a retrospective study in 174 patients, 6 patients with negative history of FB aspiration were diagnosed during bronchoscopy⁽¹⁰⁾.

Computed tomography scan imaging is an adjunct in managing FB aspiration. It may be performed prior to bronchoscopy as a diagnostic tool, in the case of negative history and normal chest radiograph, but with persistent symptoms of cough and recurrent pneumonia.

In our case, the initial chest radiograph had raised a suspicion of a FB; however since there was no history of FB inhalation, but a concurrent history of bronchial asthma, the diagnosis was missed. Chest radiograph confirmed the presence of a tubular radio-opaque FB in the right main bronchus, while the right lung was hyperinflated. As his condition did not improve, a repeated chest radiograph was performed and showed that the FB had migrated to the left main bronchus, occluding the bronchus and leading to left lung collapse. The child was referred for an urgent bronchoscopy and a chicken bone lodged at the left main bronchus was removed. The rest of the bronchial tree was normal and no pus or granulation tissue was detected. A repeated follow-up chest radiograph after bronchoscopy confirmed that the lung collapse has resolved and the child's clinical condition improved.

CONCLUSION

A thorough patient's history is vital in FB aspiration in children with respiratory symptoms and those with suspicious radiograph findings. The earlier the diagnosis of FB aspiration, the lesser the risk of complications.

Conflict of interest

The authors do not declare any financial or personal links to other persons or organisations that could adversely affect the content of this publication or claim rights thereto.

References

- Centers for Disease Control and Prevention (CDC): Nonfatal choking-related episodes among children – United States, 2001. *MMWR Morb Mortal Wkly Rep* 2002; 51: 945–948.
- Shivakumar AM, Naik AS, Prashanth KB et al.: Tracheobronchial foreign bodies. *Indian J Pediatr* 2003; 70: 793–797.
- Chiu CY, Wong KS, Lai SH et al.: Factors predicting early diagnosis of foreign body aspiration in children. *Pediatr Emerg Care* 2005; 21: 161–164.
- Cataneo AJ, Cataneo DC, Ruiz RL Jr: Management of tracheobronchial foreign body in children. *Pediatr Surg Int* 2008; 24: 151–156.
- Passali D, Lauriello M, Bellussi L et al.: Foreign body inhalation in children: an update. *Acta Otorhinolaryngol Ital* 2010; 30: 27–32.
- Mu L, He P, Sun D: The causes and complications of late diagnosis of foreign body aspiration in children. Report of 210 cases. *Arch Otolaryngol Head Neck Surg* 1991; 117: 876–879.
- Zerella JT, Dimler M, McGill LC et al.: Foreign body aspiration in children: value of radiography and complications of bronchoscopy. *J Pediatr Surg* 1998; 33: 1651–1654.
- Steen KH, Zimmermann T: Tracheobronchial aspiration of foreign bodies in children: a study of 94 cases. *Laryngoscope* 1990; 100: 525–530.
- Black RE, Johnson DG, Matlak ME: Bronchoscopic removal of aspirated foreign bodies in children. *J Pediatr Surg* 1994; 29: 682–684.
- Karakoç F, Karadağ B, Akbenlioğlu C et al.: Foreign body aspiration: what is the outcome? *Pediatr Pulmonol* 2002; 34: 30–36.
- Poukkula A, Ruotsalainen EM, Jokinen K et al.: Long-term presence of a denture fragment in the airway (a report of two cases). *J Laryngol Otol* 1988; 102: 190–193.