

Mohd Shaiful Nizam Mamat Nasir<sup>1,2</sup>, Suhaimi Yusof<sup>2</sup>,  
Muhammad Nasri Abu Bakar<sup>2</sup>, Irfan Mohamad<sup>1</sup>

Received: 28.04.2018  
Accepted: 17.07.2018  
Published: 31.12.2018

## A suspicious non-healing wound of the pinna

### Podejrzana, niegojąca się rana małżowiny usznej

<sup>1</sup> Department of Otorhinolaryngology, Head & Neck Surgery, School of Medical Sciences, Universiti Sains Malaysia Health Campus, 16150 Kota Bharu, Kelantan, Malaysia

<sup>2</sup> Department of Otorhinolaryngology, Hospital Tengku Ampuan Afzan, 25100 Kuantan, Pahang, Malaysia

Correspondence: Mohd Shaiful Nizam bin Mamat Nasir, Department of Otorhinolaryngology, Head & Neck Surgery, School of Medical Sciences, Universiti Sains Malaysia Health Campus, 16150 Kota Bharu, Kelantan, Malaysia; Department of Otorhinolaryngology, Hospital Tengku Ampuan Afzan, 25100 Kuantan, Pahang, Malaysia, e-mail: drshaiful10@gmail.com

#### Abstract

Squamous cell carcinoma of the pinna occurs primarily in older males who are exposed to sunlight for a prolonged period. Most squamous cell carcinomas of the pinna are well differentiated and present as a painless mass or a sessile nodule. We describe an interesting case of an adult woman with a non-healing wound located on the right pinna which was treated conservatively, and was later diagnosed as squamous cell carcinoma.

**Keywords:** pinna, squamous cell carcinoma, wound

#### Streszczenie

Rak kolczystokomórkowy skóry zlokalizowany w obrębie małżowiny usznej występuje głównie u mężczyzn w starszym wieku, którzy są narażeni na długotrwałe działanie promieni słonecznych. W większości przypadków nowotwór ten jest dobrze zróżnicowany i ma postać niebolesnej masy lub nieuszypułowanego guzka. W pracy opisujemy ciekawy przypadek dorosłej kobiety z niegojącą się raną prawej małżowiny usznej – pacjentkę leczono zachowawczo, zanim ustalono rozpoznanie raka kolczystokomórkowego.

**Słowa kluczowe:** małżowina uszna, rak kolczystokomórkowy skóry, rana

## INTRODUCTION

Squamous cell carcinoma (SCC) of the pinna is a type of skin carcinoma. It has a high rate of metastasis, amounting to about 16%, to the intraglandular lymph nodes of the parotid and cervical lymph nodes. In other cutaneous SCC in the head region that originate elsewhere, including the scalp, forehead, mastoid, cheek, nose and neck, the rate of metastasis is only 0.5–2%<sup>(1,2)</sup>. Men over 60 years old with a prolonged history of exposure to the sun are commonly affected. The history of immune suppression or ultraviolet exposure are strongly associated with a worse prognosis<sup>(3)</sup>. SCCs rarely cause mortality but the quality of life is definitely affected.

## CASE SUMMARY

A 68-year-old female presented with a non-healing wound on the right pinna of one month's duration. Initially, it started as dried skin with occasional itchiness, and turned into a worsening wound after the skin peeled off (Fig. 1).

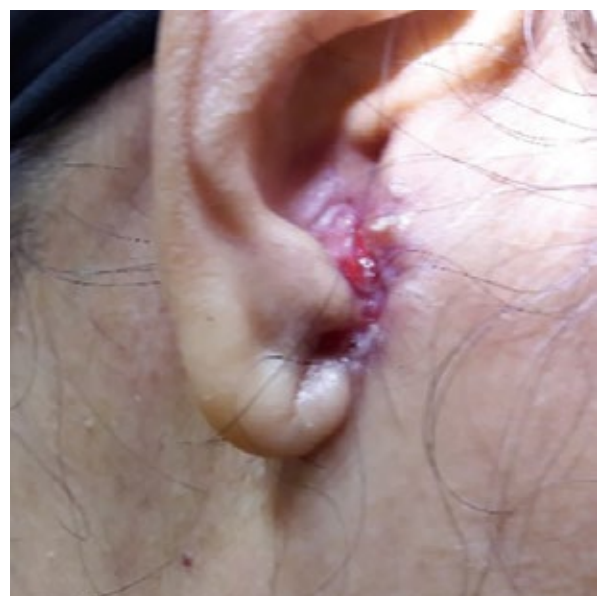


Fig. 1. Wound at the right external meatus extending into the ear lobe

It was associated with serous discharge. There was no history of fever, insect bite or ear trauma. After unsuccessful one-week oral antibiotic therapy followed by toilet and suturing a week later, an urgent tissue biopsy was performed which revealed SCC.

Otologic examination revealed an ulcerative wound measuring approximately  $2 \times 1$  cm and extending from the right intertragic notch to the external meatus. The general physical examination and oropharyngeal examination were unremarkable, and the patient exhibited neither cranial nerves deficits nor lymphadenopathy.

With the tumour encroaching the external meatus, temporal high-resolution computed tomography (HRCT) was performed to look for evidence of temporal bone involvement or another differential such as external auditory canal (EAC) tumour. Fortunately, there was no temporal bone involvement and no evidence of EAC tumour.

As the lesion was small, an excisional biopsy with local flap for wound closure was opted for (Fig. 2). Histopathology examination (HPE) confirmed the diagnosis of moderately differentiated SCC. Based on HPE, the tumour was 5 mm away from the external auditory canal margin, 10 mm away from the lobule margin, 5 mm away from the tragus margin and 3 mm from the base margin. The symba concha margin was not involved ( $>20$  mm). One month after the operation the patient had no postsurgical complications or new swelling (Fig. 3). She was referred for radiotherapy and will be under our follow-up for at least for 2 years.

## DISCUSSION

SCC of the head and neck accounts for one-fourth of all SCC cases<sup>(4)</sup>. Carcinoma of the pinna accounts for about

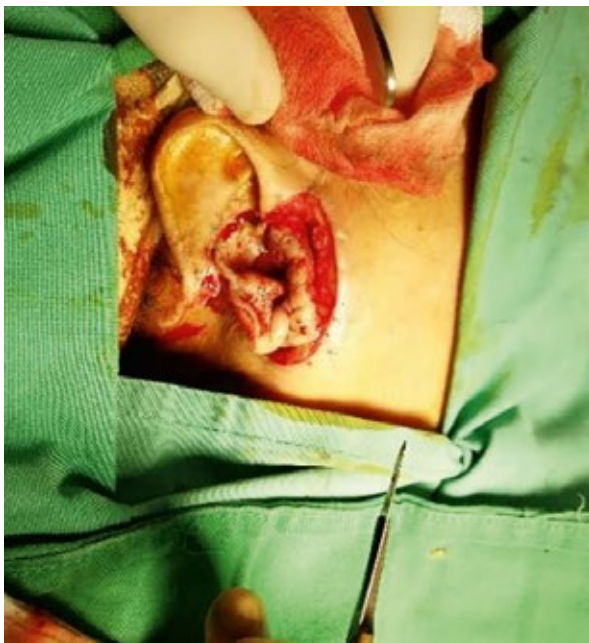

Fig. 2. Wide local excision with local flap performed

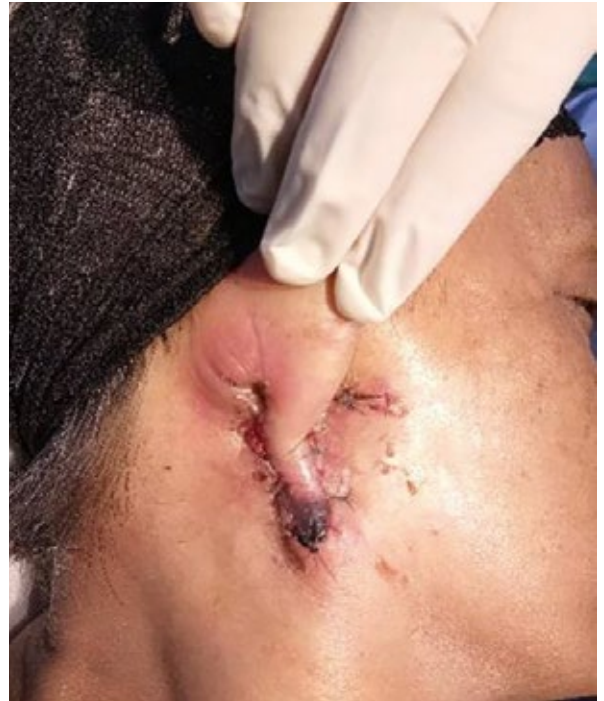

Fig. 3. Postoperative follow-up

6% of all cutaneous malignancies, in which 50–60% are SCC, 30–40% are basal cell carcinomas (BCC), and 2–6% are malignant melanomas<sup>(5)</sup>. Carcinoma of the pinna and the external canal usually presents as a slow growing painless mass. However, itchiness, pain and minor bleeding may occur as the lesion enlarges if it is left untreated<sup>(6)</sup>. Our case did not follow the classical presentation such as a slow growing painless mass, but the patient presented with a non-healing wound despite conservative treatment.

It is generally believed that SCC of the pinna has a higher rate of metastasis than SCC at other sites on the skin, and that it is associated with a worse prognosis due to its close proximity to the base of the skull, temporal bone, facial nerve and parotid gland<sup>(7)</sup>. The most common sites were found to be the helix (32.9%), followed by posterior pinna (31.6%) and antihelix (11.8%)<sup>(8)</sup>.

A high risk of tumour metastasis is based on the depth of invasion or tumour volume in conjunction with evidence of cartilage destruction. There was a positive correlation between cartilage destruction and development of metastases ( $p = 0.003$ )<sup>(1)</sup>. Fortunately in our case, in the HPE report, the section showed malignant squamous cells arranged in trabeculae, islands and nest with an area of ulceration, but no cartilage invasion.

Surgery is the preferred treatment modality for SCC of the pinna, ranging from simple excision and direct closure, wedge excision, local flap to more radical procedures like pinnectomy. Aggressive surgical treatment with postoperative radiotherapy should be reserved for more advanced, persistent and recurrent cases<sup>(9)</sup>.

## CONCLUSION

Suspicion should arise and biopsy is mandatory whenever a non-healing wound or ulcer fails to respond to appropriate conservative therapy. The treatment of pinna carcinoma, especially in this location, must take into consideration the balance between adequate eradication and the ultimate cosmetic appearance.

### Conflict of interest

*The authors do not declare any financial or personal links to other persons or organisations that could adversely affect the content of this publication or claim rights thereto.*

## References

1. Clark RR, Soutar DS, Hunter KD: A retrospective analysis of histological prognostic factors for the development of lymph node metastases from auricular squamous cell carcinoma. *Histopathology* 2010; 57: 138–146.
2. Mourouzis C, Boynton A, Grant J et al.: Cutaneous head and neck SCCs and risk of nodal metastasis – UK experience. *J Craniomaxillofac Surg* 2009; 37: 443–447.
3. Yoon M, Chougule P, Dufresne R et al.: Localized carcinoma of the external ear is an unrecognized aggressive disease with a high propensity for local regional recurrence. *Am J Surg* 1992; 164: 574–577.
4. Avila J, Bosch A, Aristizábal S et al.: Carcinoma of the pinna. *Cancer* 1977; 40: 2891–2895.
5. Vuyk HD, Cook TD: Auricular reconstruction after Mohs' surgery. A review. *Face* 1997; 5: 9–21.
6. Cassisi NJ: Neoplasms of the auricle. In: Cummings CW, Fredrickson JM, Harker LE et al. (eds.): *Otolaryngology – Head and Neck Surgery*. 2<sup>nd</sup> ed., Mosby-Year Book, St. Louis, MO 1993: 2965.
7. Shiffman NJ: Squamous cell carcinomas of the skin of the pinna. *Can J Surg* 1975; 18: 279–283.
8. Mayo E, Sharma S, Horne J et al.: Squamous cell carcinoma of the pinna: which histological features could be used to predict prognosis? *Br J Oral Maxillofac Surg* 2017; 55: 524–529.
9. Thomas SS, Matthews RN: Squamous cell carcinoma of the pinna: a 6-year study. *Br J Plast Surg* 1994; 47: 81–85.