

Received: 01.08.2018

Accepted: 12.12.2018

Published: 31.05.2019

Adam J. Sybilski<sup>1,2</sup>

## Croup – the most important questions and answers

### Zespół krupu – najważniejsze pytania i odpowiedzi

<sup>1</sup> Department of Environmental Hazards Prevention and Allergology, Medical University of Warsaw, Warsaw, Poland

<sup>2</sup> Department of Paediatrics and Neonatology, Centre for Allergology and Dermatology, Central Clinical Hospital of the Ministry of the Interior, Warsaw, Poland

Correspondence: Adam J. Sybilski, MD, PhD, Department of Paediatrics and Neonatology, Centre for Allergology and Dermatology, Central Clinical Hospital of the Ministry of the Interior, Wołoska 137, 02-507 Warszawa, Poland, tel.: +48 22 508 12 20, e-mail: adam.sybilski@cskmswia.pl

#### Abstract

Until the end of the first half of the 20<sup>th</sup> century croup was associated mainly with diphtheria caused by *Corynebacterium diphtheriae*. However, now the term “croup” covers a whole group of disorders of the larynx, trachea and bronchi. The term refers to a number of disorders included in ICD-10 and may be used as a synonym for acute laryngitis, laryngotracheitis and laryngotracheobronchitis. The group of diseases included under the term “croup” is particularly dangerous for children: due to specific anatomical and physiological features stridor may only occur when a child is crying or moving. The most common aetiological factors for acute laryngotracheitis are viruses (e.g. parainfluenza). Croup may also be caused by bacteria. Typical symptoms include stridor, cough (barking, seal-like), hoarseness and activation of accessory respiratory muscles. As the disease progresses, upper airway obstruction and laryngeal dyspnoea increase and the patient develops tachypnoea with a prolonged inspiratory phase. The child's anxiety increases. The course of the disease and the ultimate level of airway obstruction may vary. The diagnosis of croup symptoms is based on physical examination and interview. Initially, the severity of symptoms should be assessed using the Westley score. Pharmacotherapy includes glucocorticoids (nebulised, oral, parenteral) and adrenaline (nebulised). In Poland, the first line therapy for croup is nebulised glucocorticoids. The oral and inhaled route of administration of glucocorticoids are equally recommended. In severe forms of croup oxygen may be administered.

**Keywords:** croup, acute laryngotracheitis, glucocorticoids, respiratory obstruction, children

#### Streszczenie

Do połowy XX wieku krup kojarzony był głównie z dyfterytem (błonicą) wywołanym przez *Corynebacterium diphtheriae*. Tymczasem określenie „zespół krupu” obejmuje całą grupę chorób krtani, tchawicy i oskrzeli. Pod pojęciem tym kryje się szereg jednostek chorobowych uwzględnionych w klasyfikacji ICD-10 i może ono być używane jako synonim ostrego zapalenia krtani, zapalenia krtani i tchawicy oraz zapalenia krtani, tchawicy i oskrzeli. Grupa chorób mieszcząca się pod terminem „zespół krupu” jest szczególnie niebezpieczna dla dzieci – z uwagi na ich specyficzne uwarunkowania anatomiczne i fizjologiczne, które powodują, że stridor może występować tylko wtedy, kiedy dziecko płacze lub się porusza. Najczęstszymi czynnikami etiologicznymi ostrego zapalenia krtani i tchawicy są wirusy (np. paragrypy). Zespół krupu może zostać wywołany także przez bakterie. Do typowych objawów należą: stridor, kaszel (szczekający, focy), chrypa, uruchomienie dodatkowych mięśni oddechowych. Wraz z postępem choroby nasila się niedrożność górnych dróg oddechowych, wzrasta duszność krtaniowa, pojawia się *tachypnoe* z wydłużoną fazą wdechową. Wzrasta niepokój dziecka. Przebieg choroby i ostateczny stopień niedrożności dróg oddechowych mogą być różne. Rozpoznanie symptomów zespołu krupu opiera się na badaniu przedmiotowym i podmiotowym. Początkowo należy ocenić nasilenie objawów na podstawie skali Westleya. W farmakoterapii stosuje się glikokortykosteroidy (w nebulizacji, doustnie, parenteralnie) oraz adrenalinę (w nebulizacji). W Polsce podstawowym lekiem w terapii zespołu krupu są glikokortykosteroidy w nebulizacji. Doustna i inhalacyjna forma podania glikokortykosteroidów są jednakowo rekomendowane. W ciężkich postaciach krup można podać tlen do oddychania.

**Słowa kluczowe:** zespół krupu, ostre zapalenie krtani i tchawicy, glikokortykosteroidy, niedrożność oddechowa, dzieci

## CROUP: WHAT IS IT ALL ABOUT?

The term “croup” defined as typical symptoms of laryngotracheitis: barking cough, laryngeal stridor and hoarseness has not been adopted in Poland. It seems that this terminological disagreement has its roots in history. Croup used to be associated mainly with the bacterial infection caused by *Corynebacterium diphtheriae*, i.e. diphtheria. Laryngopharyngeal diphtheria is a severe acute contagious disease. In the middle of the 20<sup>th</sup> century the prevalence of diphtheria decreased rapidly, which was due to the introduction of a diphtheria vaccine. Thorough studies on bacteria and viruses have led to the conclusion that croup is caused mainly by viral infections. The view of this group of diseases has dramatically changed. In Poland, due to universal vaccination against diphtheria, which is currently called “true croup” and is listed in the International Classification of Diseases (ICD-10) under A36, no cases of diphtheria have been recorded in many years, while laryngitis and tracheitis are common<sup>(1,2)</sup>.

## CROUP: DEFINITION

The term “croup” refers to diseases of the larynx, the supra- and subglottic area and the trachea. Croup includes laryngotracheitis, laryngotracheobronchitis and subglottic laryngitis (so-called pseudocroup). Currently, the terms “croup” or “croup syndrome” are used for diseases characterised by upper respiratory tract symptoms and complaints typical for laryngitis, tracheitis and sometimes bronchitis (Tab. 1).

Condition	Characteristics
Acute laryngitis • oedematous • subglottic • suppurative	Inflammation of the larynx, often of viral origin, with hoarseness; stridor may occur
Epiglottitis (supraglottitis)	Usually bacterial, involves the epiglottis and vocal folds, leads to airway obstruction
Acute laryngotracheitis	Inflammation of the larynx and trachea, often of viral origin (parainfluenza, influenza)
Laryngotracheobronchitis	Very rare, originally viral condition, usually a severe complication of subglottic laryngitis; it is a life-threatening emergency and always requires intubation
Laryngeal diphtheria (Latin: <i>laryngitis croup</i> )	<i>Corynebacterium diphtheriae</i> infection of the larynx; may involve other parts of the respiratory tract; leads to obstruction, stridor and dyspnoea
Diphtheria, laryngopharyngeal diphtheria	Severe acute bacterial disease ( <i>Corynebacterium diphtheriae</i> ); the bacteria cause tissue necrosis, or so-called pseudomembranes
Laryngeal constriction, subglottic allergic oedema of the larynx (spasmodic laryngitis/croup)	Sudden onset (usually at night) with severe inspiratory stridor; may be accompanied with a mild upper respiratory tract infection

Tab. 1. Croup diseases<sup>(1,3 – modified by the author)</sup>

<b>J04 Acute laryngitis and tracheitis</b>	J04.0 Acute laryngitis • NOS* • oedematous • subglottic • suppurative • ulcerative
	J04.1 Acute tracheitis • NOS* • catarrhal
	J04.2 Acute laryngotracheitis • laryngotracheitis NOS* • tracheitis (acute) with laryngitis (acute)
<b>J05 Acute obstructive laryngitis and epiglottitis</b>	J05.0 Acute obstructive laryngitis
	J05.1 Acute epiglottitis
<b>J06 Acute laryngopharyngitis</b>	
* Not otherwise specified.	

Tab. 2. Conditions classified as croup as listed in ICD-10

ICD-10 does not include croup or croup syndrome; however, in accordance with medical literature, acute laryngitis and tracheitis, particularly of viral origin, should be included under J04–J06 (Tab. 2)<sup>(1,3)</sup>.

## WHY IS CROUP PARTICULARLY DANGEROUS FOR CHILDREN?

Diseases referred to as croup are particularly dangerous for children, since children are more likely to experience acute airway obstruction than adults. Due to specific anatomical and physiological features in children (Tab. 3) stridor may occur only when the child is crying or moving<sup>(4–6)</sup>.

## IS CROUP COMMON?

Diseases referred to as croup (mainly acute and subglottic laryngitis) are most common in children aged 6 months to 3 years. They sometimes affect younger infants (approximately 3 months of age) and preschool children. However, they are rare in children older than 6 years. These diseases are more common in boys than in girls (1.4 vs. 1)<sup>(7,8)</sup>. Croup is extremely rarely diagnosed in adults<sup>(9,10)</sup>. The majority of cases of the disease occur in the autumn and winter, with peaks at times of increased incidence of parainfluenza (often in October). The most severe symptoms usually occur between 10 p.m. and 4 a.m.<sup>(11)</sup>.

- Narrow airway
- Weak respiratory tract walls
- Anatomical constrictions of the supra- and subglottic area
- Uvula disproportionately large compared to the size of the oral cavity
- Wider and longer epiglottis
- Larynx more superior and anterior than in adults
- Weaker and more fibrous diaphragm
- Decreased mechanical force of the thoracic walls
- Immature accessory chest muscles
- Mucosa rich in mucinous glands: increased mucus production
- Increased turbulent air flow

Tab. 3. Anatomical and physiological features of children resulting in an increased risk of dyspnoea

## WHAT ARE THE RISK FACTORS?

Risk factors for croup and recurrent laryngeal dyspnoea are determined mainly based on the family history (cases of laryngitis in siblings and parents mean an over four times higher risk). A number of studies also confirm the role of IgE-mediated allergy (immediate-onset) in increasing the rate of upper airway obstruction and exacerbating the symptoms of the disease<sup>(1)</sup>. Parental smoking (a risk factor for respiratory infections) does not increase the prevalence of croup<sup>(12)</sup>.

## WHAT IS THE AETIOLOGY OF CROUP?

Croup is associated mainly with viral upper respiratory tract infections. A bacterial infection may be secondary to a viral infection.

The most common aetiological factors for croup (acute laryngotracheitis) include:

- type 1 parainfluenza virus (as many as up to 43% of cases), particularly in the autumn and winter;
- type 2 parainfluenza virus (responsible for milder forms of the disease);
- type 3 parainfluenza virus (sporadic cause of the disease, but with a more severe course);
- respiratory syncytial virus (RSV) and adenoviruses (they are relatively frequent causes of laryngitis, with upper respiratory tract symptoms being much less severe than lower respiratory tract symptoms);
- human coronavirus NL63 (HCoV-NL63);
- measles virus (very rarely, occurring primarily in areas where the virus is common);
- influenza virus (a relatively rare cause of croup)<sup>(1,13)</sup>.

The most severe course of laryngitis is found in type A influenza virus infection. Children hospitalised for influenza with croup symptoms usually stay longer in hospital. They are also more likely to be readmitted due to recurrence of laryngeal symptoms.

Croup may also be caused by the following bacteria:

- *Mycoplasma pneumoniae* (associated with mild cases of the disease);
- *Haemophilus influenzae* (as a secondary infection and transformation of acute laryngitis into severe forms of epiglottitis or laryngotracheobronchitis – LTB);
- *Staphylococcus aureus*, *Streptococcus pyogenes* and *Streptococcus pneumoniae* (most common secondary bacterial pathogens).

## WHAT ARE THE CHARACTERISTIC SYMPTOMS?

The initial symptoms are not alarming and suggest a trivial cold. Rhinitis (discharge, blockage) and sometimes sore throat and a slight hoarseness occur. However, within 12–48 hours acute laryngotracheitis symptoms develop.

Typical symptoms include:

- stridor;
- cough (barking, seal-like);
- hoarseness;
- activation of accessory respiratory muscles;
- fever of 37.8–40.5°C (although it does not have to occur).

As the disease progresses and upper airway obstruction increases, laryngeal dyspnoea deteriorates and the patient develops tachypnoea with a prolonged inspiratory phase. The child's anxiety increases. Physical examination may reveal hoarseness, audible laryngeal stridor, rhinitis, pharyngeal congestion and tachypnoea.

The ultimate level of airway obstruction in a developing disease may vary. Some children develop hoarseness and barking cough, but have no other signs of obstruction. In such cases the disease is self-limiting and its symptoms last approximately 3–7 days and subsequently gradually subside. However, sometimes obstruction progresses leading to severe respiratory failure with an increased work of breathing, cyanosis of various degrees, and anxiety. Hypoxia increases heart rate. In severe cases, the duration of the disease, regardless of the therapy administered, is rarely shorter than 7 days and may extend to as many as 14 days.

## HOW CAN CROUP BE DIAGNOSED?

The diagnosis of diseases referred to as croup is based on clinical examination (physical examination and interview). The presence of the characteristic barking (seal-like) cough and laryngeal stridor is of particular importance for the diagnosis. Radiological and additional examinations are not necessary.

## HOW TO DIFFERENTIATE BETWEEN CROUP DISEASES?

At the initial stage of the disease determining the correct diagnosis may be difficult. Due to the need to apply the right course of treatment differential diagnosis of acute laryngeal dyspnoea should always be performed (Fig. 1). Tab. 4 presents the most important features of and differences between five causes of laryngeal stridor and upper airway obstruction<sup>(1)</sup>.

## WHAT TO DO IF CROUP IS SUSPECTED?

1. First, assess the severity of croup symptoms (Tab. 5) since further management of the patient depends on this. Westley score can also be used to assess the severity of symptoms (Tab. 6)<sup>(15)</sup>.
2. Identify patients with a severe form and rapid progression of the disease.
3. Commence therapy.

## HOW TO TREAT CROUP?

Both pharmacological and non-pharmacological methods are used to treat croup. Depending on the severity

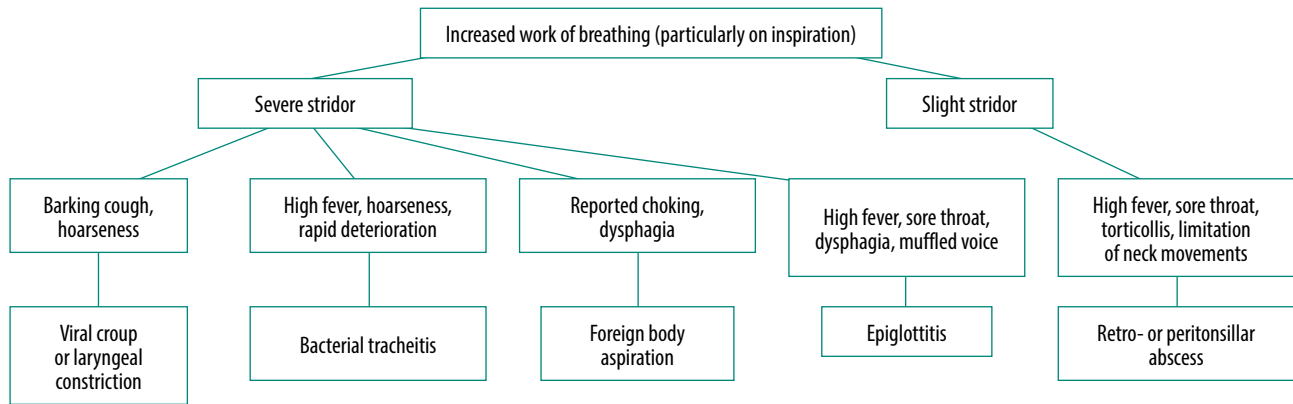


Fig. 1. Clinical approach to differential diagnosis of acute-onset croup in children<sup>(14)</sup>

of the disease and the available resources, treatment is conducted at home, at an emergency or paediatric department or at an intensive care unit (ICU).

Pharmacotherapy includes:

- nebulised, oral, parenteral glucocorticoids (GC); none of these routes of administration shows any significant clinical advantage over others<sup>(3)</sup>;
- nebulised adrenaline (currently there is no registered nebulised formulation in Poland).

**Nebulised GC are first-line therapy for croup in Poland.**

The treatment algorithm depends on the preliminary assessment of the severity of croup (Fig. 2)<sup>(14,16,17)</sup>. However, in Poland, the presented treatment regimen must be modified. Due to the lack of a nebulised adrenaline formulation, GC are considered to be the primary medication for croup. The oral and inhaled route of administration of GC are equally recommended<sup>(1,18)</sup>. However, according to the author's experience, inhalation is a more comfortable and effective solution in Poland considering access to inhalers and the prices of inhalation products. Inhalation delivers the medicine to the site of the disease quickly (after

	Acute laryngotracheitis	Epiglottitis	Laryngotracheobronchitis (LTB)	Laryngospasm	Diphtheria
<b>Typical age</b>	3 months – 3 years	1 year – 8 years	3 months – 3 years	3 months – 3 years	Any age
<b>Family history</b>	Familial predisposition	Not important	Possible familial predisposition	Familial predisposition; often a history of episodes	No vaccination
<b>Initial symptoms</b>	Usually rhinitis	Sometimes rhinitis	Usually rhinitis	Slight rhinitis	Usually pharyngitis
<b>Progression to full-blown croup</b>	Moderately rapid – 12–48 h	Rapid – 4–12 h	Usually slowly progressing – 12 h – 7 days	Sudden, usually at night	Slow – 2–3 days
<b>Symptoms of disease (based on patient's history)</b>					
<b>Fever</b>	Yes; fluctuating, 37.8–40.5°C	Yes; usually approximately 39.5°C	Yes; fluctuating, 37.8–40.5°C	Absent	Yes; usually 37.8–38.5°C
<b>Hoarseness and barking cough</b>	Yes	Absent	Yes	Yes	Yes
<b>Dysphagia</b>	Yes	Absent	Yes	Yes	Yes
<b>Inspiratory dyspnoea</b>	Yes; mild or moderate	Yes; moderate and severe	Yes; usually severe	Yes; moderate	Yes; mild or moderate
<b>Toxic appearance</b>	Usually mild	Severe	Usually moderate, may be severe	Absent	Usually absent
<b>Signs of disease</b>					
<b>Oral cavity</b>	Mild pharyngitis	Pharyngitis, excessive salivation	Usually slight pharyngitis	NC*	Pharyngeal diphtheria
<b>Epiglottitis appearance</b>	NC*	Raspberry red, oedema	NC*	NC*	Usually NC*; sometimes membranous coating
<b>Radiographic examination</b>	Subglottic constriction in AP** view	Epiglottic oedema in lateral view	Subglottic constriction in AP** view	Not useful	Not useful
<b>Clinical course</b>	Various rate of dyspnoea progression; usually does not require any procedure	Rapid development of disease; rapid cardiorespiratory failure	Very severe signs of airway constriction; may persist for 7–14 days	If treated, symptoms stay for a short time; symptoms may recur	Slow progression of disease

\* No change.

\*\* Anteroposterior view.

Tab. 4. Differential diagnosis of croup diseases<sup>(1,6 – modified by the author)</sup>

Degree of severity based on clinical symptoms
<b>Mild</b> <ul style="list-style-type: none"> <li>Sporadic cough</li> <li>No stridor at rest</li> <li>Absent or mild retraction of intercostal spaces</li> </ul>
<b>Moderate</b> <ul style="list-style-type: none"> <li>Severe, frequent cough</li> <li>Easily audible stridor at rest</li> <li>Retraction of intercostal spaces at rest</li> <li>Absent or slight anxiety or excitement</li> </ul>
<b>Severe</b> <ul style="list-style-type: none"> <li>Frequent, severe, barking cough</li> <li>Strong inspiratory and expiratory stridor</li> <li>Visible considerable chest retraction</li> <li>Significant anxiety or excitement</li> </ul>
<b>Life-threatening respiratory failure</b> <ul style="list-style-type: none"> <li>Barking cough (may be invisible)</li> <li>Audible stridor at rest</li> <li>Chest wall retraction</li> <li>Lethargy or decreased level of consciousness</li> <li>Substantial cyanosis</li> </ul>

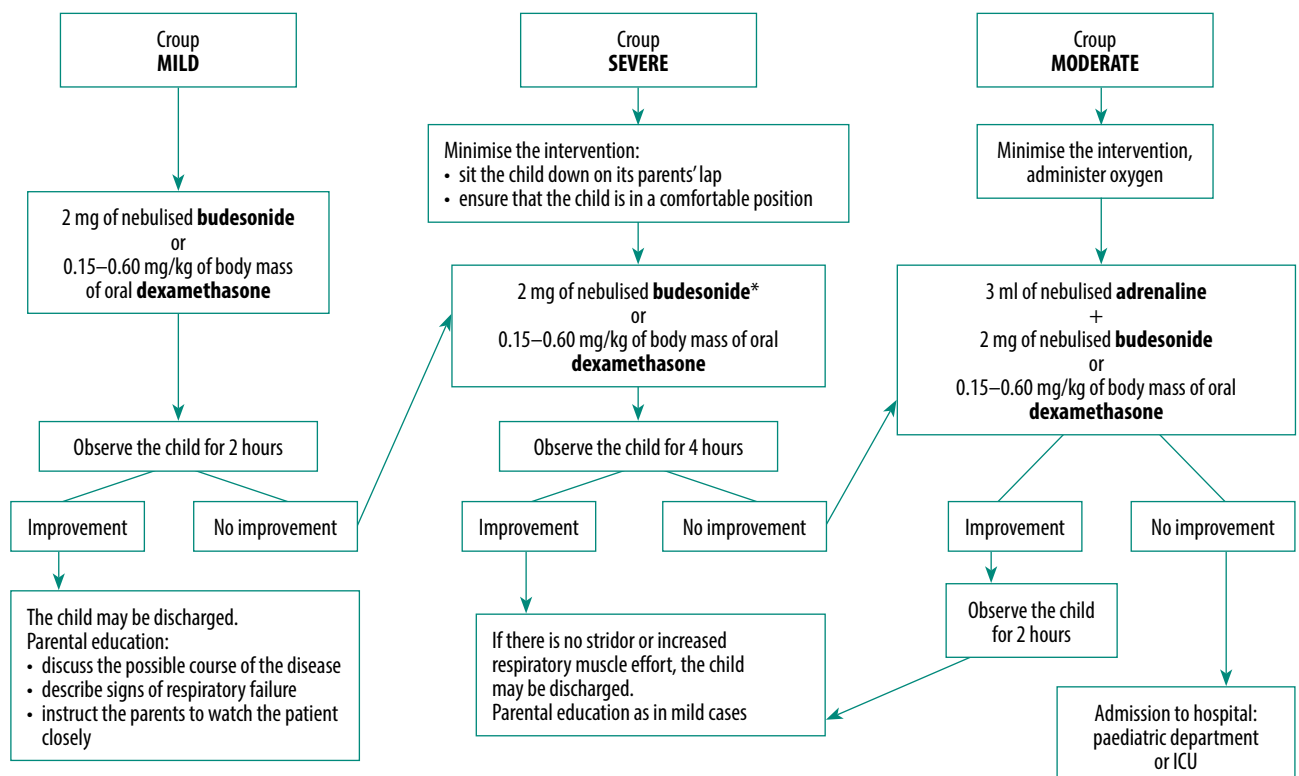
Tab. 5. Assessment of croup severity

oral administration the effect is seen after 2–3 hours from administration), does not require the child's cooperation (swallowing a tablet) and is safer (if the child does not cooperate well and suffers from severe dyspnoea and coughing there is a risk of choking; there is also no GC in the form of a suspension or syrup available in Poland). For older children, oral administration of GC in a single dose is the right and in many countries preferred action to take.

Sign		Score
Consciousness	Normal	0
	Impaired	5
Cyanosis	None	0
	With activity	4
	At rest	5
Stridor	None	0
	With activity	1
	At rest (audible without auscultation)	2
Air entry	Normal	0
	Impaired	1
	Markedly impaired	2
Chest wall retractions	None	0
	Mild	1
	Moderate	2
	Severe	3

Tab. 6. Westley Croup Score Criteria: from 0 to 17 points<sup>(15 – modified by the author)</sup>

The efficacy of GC (inhaled budesonide and oral dexamethasone) was confirmed by a Cochrane database analysis of 2011. The authors of the analysis concluded that GC are effective in mitigating the symptoms of croup, reduce the duration of hospital stay and decrease the number of readmissions to hospital<sup>(19)</sup>. However, GC should not be administered in such croup diseases as epiglottitis and LTB combined with pneumonia<sup>(1)</sup>. If GC produce an insufficient effect or it is not possible to use them in moderate or severe forms of the disease, the administration of nebulised adrenaline (from an ampoule) may be considered, although one should bear in mind that it is an off-label use of the medicinal product.



\* Nebulised adrenaline may also be considered in moderate forms of the disease.



In severe forms of croup oxygen may be administered. There is no evidence of a direct effect of oxygen on laryngeal oedema and airway constriction; however, in children with hypoxaemia (with saturation <92%) oxygen should be administered<sup>(1)</sup>. Some authors suggest the use of heliox (a mix of oxygen and helium), although in Poland this solution is restricted by its availability and price<sup>(17,20)</sup>.

Comparative studies have not demonstrated humidified air to be effective<sup>(21,22)</sup>. This is because humidified air does not reduce subglottic oedema of the larynx; at most, it reduces airway dryness and makes discharge more liquid. Sometimes the use of inhaler as a source of mist may provide a sense of comfort and calm both to the child and its caregivers.

Antibiotics are administered for superinfections or a disease with an originally bacterial aetiology (e.g. epiglottitis). The following medicines are not recommended: cough suppressants, short-acting  $\beta_2$ -agonists as bronchodilators, first- and second-generation antihistamines and anticholinergics<sup>(23)</sup>.

### WHAT TO REMEMBER?

1. Croup is a group of diseases of the larynx, trachea and bronchi which are characterised by the presence of barking cough, stridor and hoarseness. The term “croup” covers a number of diseases included in ICD-10. As a result, this term can be used as a synonym for acute laryngitis, laryngotracheitis and laryngotracheobronchitis.
2. These days, the term “croup” does not have to refer to diphtheria, since there have been no cases of this disease in Poland for years.
3. The diagnosis is based on characteristic clinical symptoms and is usually unproblematic.
4. Croup is usually caused by viruses, and, consequently, the present standard of care is the administration of nebulised or oral GC.

### Conflict of interest

*The author does not report any financial or personal affiliations to persons or organisations that could adversely affect the content of or claim to have rights to this publication.*

### References

1. Tovar Padua LJ, Cherry JD: Croup (laryngitis, laryngotracheitis, spasmodic croup, laryngotracheobronchitis, bacterial tracheitis, and laryngotracheobronchopneumonitis) and epiglottitis (supraglottitis). In: Cherry JD, Harrison GJ, Kaplan SL et al. (eds.): Feigin and Cherry's Textbook of Pediatric Infectious Diseases. 8<sup>th</sup> ed., Elsevier, Philadelphia 2019: 175–190.
2. Szczepionka przeciw błonicy. Available from: <http://szczepienia.pzh.gov.pl/szczepionki/blonica/> [cited: 20 July 2018].
3. Emeryk A: Zespół krup u dzieci – epidemiologia, diagnostyka, postępowanie. Klin Pediatr 2014; 22: 17–22.
4. Mandal A, Kabra SK, Lodha R: Upper airway obstruction in children. Indian J Pediatr 2015; 82: 737–744.
5. Wani TM, Bissonnette B, Rafiq Malik M et al.: Age-based analysis of pediatric upper airway dimensions using computed tomography imaging. Pediatr Pulmonol 2016; 51: 267–271.
6. Marchese A, Langan ML: Management of airway obstruction and stridor in pediatric patients. Pediatr Emerg Med Pract 2017; 14: 1–24.
7. Bjornson CL, Johnson DW: Croup. Lancet 2008; 371: 329–339.
8. Cherry JD: Clinical practice. Croup. N Engl J Med 2008; 358: 384–391.
9. Tachibana T, Orita Y, Makino T et al.: Prognostic factors and importance of recognition of adult croup. Acta Otolaryngol 2018; 138: 579–583.
10. Patel JJ, Kitchin E, Pfeifer K: A narrowing diagnosis: a rare cause of adult croup and literature review. Case Rep Crit Care 2017; 2017: 9870762.
11. Lee DR, Lee CH, Won YK et al.: Clinical characteristics of children and adolescents with croup and epiglottitis who visited 146 Emergency Departments in Korea. Korean J Pediatr 2015; 58: 380–385.
12. Pruikkonen H, Dunder T, Renko M et al.: Risk factors for croup in children with recurrent respiratory infections: a case-control study. Paediatr Perinat Epidemiol 2009; 23: 153–159.
13. Weinberg GA, Hall CB, Iwane MK et al.: New Vaccine Surveillance Network: Parainfluenza virus infection of young children: estimates of the population-based burden of hospitalization. J Pediatr 2009; 154: 694–699.
14. Petrocheilou A, Tanou K, Kalampouka E et al.: Viral croup: diagnosis and a treatment algorithm. Pediatr Pulmonol 2014; 49: 421–429.
15. Westley CR, Cotton EK, Brooks JG: Nebulized racemic epinephrine by IPPB for the treatment of croup: a double-blind study. Am J Dis Child 1978; 132: 484–487.
16. Nierengarten MB: Diagnosis and management of croup in children. Contemp Pediatr 2015; 32: 31–33.
17. Ortiz-Alvarez O: Acute management of croup in the emergency department. Paediatr Child Health 2017; 22: 166–173.
18. Rittichier KK: The role of corticosteroids in the treatment of croup. Treat Respir Med 2004; 3: 139–145.
19. Russell KF, Liang Y, O'Gorman K et al.: Glucocorticoids for croup. Cochrane Database Syst Rev 2011; (1): CD001955.
20. Moraa I, Sturman N, McGuire T et al.: Heliox for croup in children. Cochrane Database Syst Rev 2013; (12): CD006822.
21. Neto GM, Kentab O, Klassen TP et al.: A randomized controlled trial of mist in the acute treatment of moderate croup. Acad Emerg Med 2002; 9: 873–879.
22. Scolnik D, Coates AL, Stephens D et al.: Controlled delivery of high vs low humidity vs mist therapy for croup in emergency departments: a randomized controlled trial. JAMA 2006; 295: 1274–1280.
23. Emeryk A: Ostre infekcje krtań, czyli jednostki chorobowe z kręgu zespołu krup u dzieci. Alergoprofil 2017; 13: 131–134.