

Received: 31.08.2018

Accepted: 18.01.2019

Published: 31.07.2019

Marcin Gładki, Magdalena Czerzyńska, Aleksandra Morka

Recurrent respiratory tract infections – a mask or a symptom of vascular sling?

Nawracające infekcje dróg oddechowych – maska czy objaw slingu naczyniowego?

Department of Paediatric Cardiac Surgery, Faculty of Health Sciences, Jagiellonian University – Medical College, Kraków, Poland

Correspondence: Magdalena Czerzyńska, Department of Paediatric Cardiac Surgery, Jagiellonian University – Medical College, Wielicka 265, 30-663 Kraków, Poland, e-mail: mmagdalencz@gmail.com

Abstract

Pulmonary artery sling is a rare congenital vascular anomaly in which the left pulmonary artery originates from the right pulmonary artery. The report presents a boy with recurrent respiratory tract infections who was continuously followed-up at a pulmonology centre since he was 2 years old. When he was 7 years old, echocardiography examination finally showed left pulmonary artery sling. Next, chest computed tomography confirmed the diagnosis and also detected bronchomalacia. Left pulmonary artery sling is a rare genetic defect that is diagnosed by echocardiography. Surgical treatment of left pulmonary artery sling at an early age prevents the development of lesions of the bronchial tree that later require long-term pulmonology treatment and rehabilitation. In case of a late diagnosis and intensified sling consequences manifest as bronchomalacia and bronchiectasis these factors will play a decisive role in the future clinical picture and the patient may need tracheoplasty treatment.

Keywords: pulmonary artery, congenital heart defect, bronchomalacia, recurrent respiratory tract infection, echocardiography

Streszczenie

Sling tętnic płucnych jest rzadką wrodzoną anomalią naczyniową, polegającą na odejściu lewej tętnicy płucnej od prawej tętnicy płucnej. Niniejszy opis prezentuje przypadek pacjenta z nawracającymi infekcjami dróg oddechowych, który był z tego powodu systematycznie badany w specjalistycznych centrach pneumonologicznych od 2. roku życia. Dopiero w wieku 7 lat badanie echokardiograficzne pomogło zdiagnozować sling tętnicy płucnej. Następnie wykonane badanie tomografii komputerowej potwierdziło rozpoznanie, uwidoczniając ponadto bronchomalację drzewa oskrzelowego. Sling lewej tętnicy płucnej jest anomalią rzadko diagnozowaną echokardiograficznie. Leczenie chirurgiczne tej wady we wczesnych latach życia zapobiega rozwojowi zmian w postaci bronchomalacji i rozstrzeni oskrzeli – w takich przypadkach niezbędna jest rehabilitacja, a nawet plastyka drzewa oskrzelowego.

Słowa kluczowe: tętnice płucne, wrodzona wada serca, bronchomalacja, nawracające infekcje dróg oddechowych, echokardiografia

BACKGROUND

Pulmonary artery sling (PAS) is a rare congenital vascular anomaly in which the left pulmonary artery (LPA) originates from the right pulmonary artery (RPA). LPA sling denotes an abnormal origin and course of LPA. LPA arises from the proximal segment of RPA and “curls” on the right margin of the trachea, extending posteriorly behind the trachea and anteriorly from the oesophagus, in the direction of the left pulmonary hilus. It is estimated that approximately 90% of the cases are detected and diagnosed in the first year of life. Late diagnoses of asymptomatic sling in adults may also happen. Echocardiography should demonstrate an abnormal course of LPA at any age; typically, there is flow acceleration, as LPA circumnavigates the trachea and bronchoscopy almost certainly demonstrates pulsation or complete rings.

CASE REPORT

The report presents a boy with recurrent respiratory tract infections who was continuously followed-up at a pulmonology centre since he was 2 years old; at the age of 7 years of life, he was diagnosed with LPA sling. Prior diagnostic management included bronchofiberscopy performed four times, which demonstrated progressive tracheomalacia and malacia of the right bronchus; computed tomography (CT) of the chest performed twice (at the age of 7 and 12 months of life), an esophagogram at 5 months of life and echocardiography (at 7 days of age and 6 months of life). The examinations failed to explain the cause of recurrent respiratory tract infections. In the view of his recurrent respiratory tract infections poorly responding to treatment (antibiotics, bronchodilators, antihistamine and antiallergic agents, inhalation and oral steroids, immunostimulatory medications) and accompanied by a significant respiratory obstructive component and

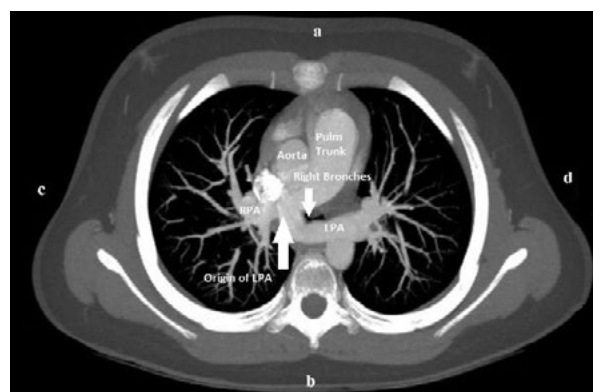


Fig. 1. Pulmonary artery sling CT scan – the left pulmonary artery (LPA) originates from the right pulmonary artery (RPA) and lies posteriorly to the trachea creating a vascular sling

chronic coughing with inhalation and exhalation wheezing and stridor, when the patient was 7 years old, accidentally, echocardiography detected left pulmonary artery originating from the right pulmonary artery.

To confirm the diagnosis, next chest CT was performed which allowed for diagnosing LPA sling, extensive tracheomalacia and bronchomalacia, mostly involving the left bronchus, with signs of bronchiectasis (Fig. 1). The delay in diagnosis establishment might have been caused by the patient's living in a small village situated far from diagnostics centres.

The patient was qualified for surgery consisting in LPA grafting in cardiopulmonary bypass and hypothermia. In reconstructing the vessel, a pulmonary homograft was employed. The postoperative effect was satisfying. Without any pharmacological support of pressor amines, despite malacia-associated lesions in the bronchial tree, the child was extubated on day “0.”

The boy was discharged on day 7 postoperatively and referred to an outpatient pulmonology clinic due to extensive lesions of the bronchial tree that required further treatment and respiratory rehabilitation. Six months after the surgery, repeated bronchoscopy confirmed extensive tracheomalacia, bronchomalacia and in consequence tracheoplasty was performed. The patient was discharged home in a good condition six days after the procedures.

Follow-up echocardiography at 20 months postoperatively demonstrated a typical origin with non-hemodynamic significant (PG, pressure gradient = 6 mm Hg) narrowing in the proximal segment of LPA, with continuously persisting domination of flow to RPA (Fig. 2).

DISCUSSION

A PAS vascular defect may occur as an isolated defect or be an element of a complex of tracheobronchial defects, i.e. segmental tracheostenosis⁽¹⁾. The vascular malformation

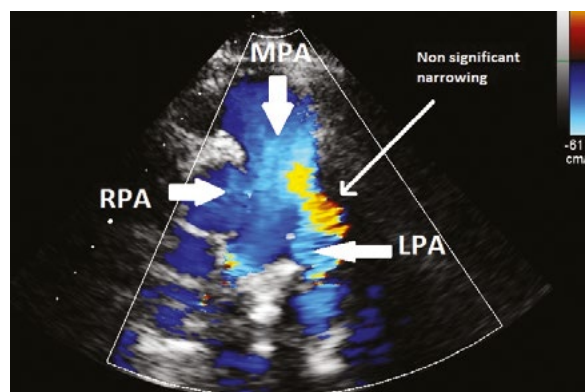


Fig. 2. Transthoracic echocardiogram performed 20 months after the primary surgical repair. Parasternal short-axis echocardiography with color and Doppler options performed 20 months after surgery demonstrated a normal LPA origin with a small, nonsignificant narrowing. The outcome was reported as normal. MPA – main pulmonary artery

may contribute to respiratory tract obturation and, in consequence, lead to progression of pathological lesions in the lungs. The progressive process often triggers the necessity of putting the patient on mechanical ventilation⁽²⁻⁴⁾.

At present, in the diagnostic management, the methods employed years ago, i.e. chest X-ray following oral barite administration and angiography of the pulmonary vessels, are gradually replaced with less invasive methods, such as ultrasonography/echocardiography, bronchofiberscopy, CT or magnetic resonance imaging^(5,6). The surgical repair procedure consists in grafting LPA to the site of its normal origin. In case of concomitant tracheal defects, tracheoplasty is performed at the same time^(7,8). Postoperative complications most often develop in patients in whom tracheoplasty has been performed^(4,8,9). The literature on the subject describes cases where prolonged ventilatory support had to be necessarily employed in the postoperative period⁽⁸⁾. Among the possible causes, the authors indicate the necessity for the respiratory system to adjust to normal functioning without compression and stenosis, or else viral infections.

In long-term follow-up, stenosis/strictures develop in the grafted LPA. This is a relatively rare phenomenon^(2,9) that may be effectively treated by balloon angioplasty⁽⁸⁾.

CONCLUSION

Recurrent respiratory tract infections without any detectable pulmonary abnormalities may be the reasons for pulmonary artery sling due to exceeded cardiology examination which should be considered.

LPA sling is a rare genetic defect that is diagnosed by echocardiography. Surgical treatment of left pulmonary artery sling at an early age prevents the development of lesions of the bronchial tree that later require long-term pulmonology treatment and rehabilitation. In case of a late diagnosis and intensified sling consequences manifested as bronchomalacia and bronchiectasis, these factors will play a decisive role in the future clinical picture and the patient may need tracheoplasty treatment.

Conflict of interest

The authors declare there is no conflict of interest nor a source of funding.

References

1. Li D, Feng Y, Hirata Y et al.: Sling pulmonary artery with bridging bronchus and narrowing airway: a case report. *Ann Thorac Cardiovasc Surg* 2017; 23: 265–267.
2. Yong MS, d'Udekem Y, Brizard CP et al.: Surgical management of pulmonary artery sling in children. *J Thorac Cardiovasc Surg* 2013; 145: 1033–1039.
3. Chung SR, Yang JH, Jun TG et al.: Clinical outcomes of slide tracheoplasty in congenital tracheal stenosis. *Eur J Cardiothorac Surg* 2015; 47: 537–542.
4. Oshima Y, Yamaguchi M, Yoshimura N et al.: Management of pulmonary artery sling associated with tracheal stenosis. *Ann Thorac Surg* 2008; 86: 1334–1338.
5. Zhong YM, Jaffe RB, Zhu M et al.: CT assessment of tracheobronchial anomaly in left pulmonary artery sling. *Pediatr Radiol* 2010; 40: 1755–1762.
6. du Plessis AM, Andronikou S, Goussard P: Bridging bronchus and sling left pulmonary artery: a rare entity demonstrated by coronal CT with 3-D rendering display and minimal-intensity projections. *Pediatr Radiol* 2008; 38: 1024–1026.
7. Huang SC, Wu ET, Wang CC et al.: Repair of complex tracheobronchial stenosis with left pulmonary artery sling and bridging bronchus. *Ann Thorac Surg* 2010; 90: 1379–1381.
8. Weber A, Donner B, Perez MH et al.: Complicated postoperative course after pulmonary artery sling repair and slide tracheoplasty. *Front Pediatr* 2017; 5: 67.
9. Manning PB, Rutter MJ, Border WL: Slide tracheoplasty in infants and children: risk factors for prolonged postoperative ventilatory support. *Ann Thorac Surg* 2008; 85: 1187–1192.