

Satesh Kumaran Ganeson¹, Jeyasakthy Saniasiaya¹, Norhaslinda Abdul Gani¹,
Aliza Ahmad², Junalina Jaafar²

Received: 21.03.2019
Accepted: 30.07.2019
Published: 20.05.2020

A rare case of cervical schwannoma: a never-ending conundrum

Rzadki przypadek guza typu *schwannoma*: niezmiennie zagadka diagnostyczna

¹ Department of Otorhinolaryngology, Hospital Tuanku Jaafar, Jalan Rasah, Bukit Rasah, 70300 Seremban, Negeri Sembilan, Malaysia

² Department of Pathology, Hospital Tuanku Jaafar, Jalan Rasah, Bukit Rasah, 70300 Seremban, Negeri Sembilan, Malaysia

Correspondence: Jeyasakthy Saniasiaya, Otorhinolaryngologist & Head and Neck Surgeon Department of Otorhinolaryngology, Hospital Tuanku Jaafar, Jalan Rasah, 70300 Seremban, Negeri Sembilan, Malaysia, tel.: +6012-6841223, e-mail: shakthy_18@yahoo.com

Abstract

Aim of the study: To emphasise the importance of meticulous history-taking and examination, and to raise the awareness of various possibilities in patient diagnosis and management. Schwannoma is a rare benign, slow-growing tumour of the nerve sheath originating from Schwann cells. Non-specific presentation of this type of mass remains a quandary mainly to the consulting physicians. At present, surgery is the main modality of treatment for this disease entity. However, surgical resection of extracranial schwannoma is often associated with major morbidity. **Case report:** We discuss a case of cervical schwannoma in a young man, presenting as a lateral neck mass initially thought to be a sebaceous cyst. Surprisingly, however, histopathological examination of the excised mass revealed it to be a schwannoma. **Conclusion:** We want to highlight the need for clinical suspicion among attending physicians in all cases involving a lateral neck mass.

Keywords: schwannoma, neurilemmoma, Schwann cells, nerve sheath tumours

Streszczenie

Cel badania: Podkreślenie znaczenia skrupulatnie zebranego wywiadu i dokładnego badania przedmiotowego pacjenta oraz zwiększenie świadomości/wiedzy co do różnych możliwości w zakresie diagnostyki i postępowania. Nerwiak osłonkowy (*schwannoma*) jest rzadkim, łagodnym, wolno rosnącym nowotworem osłonek nerwowych, wywodzącym się z komórek Schwanna. Niespecyficzna lokalizacja guzów tego typu stanowi prawdziwe wyzwanie głównie dla konsultujących lekarzy. Aktualnie główną metodą leczenia tej jednostki chorobowej jest interwencja chirurgiczna. Resekcja *schwannoma* o lokalizacji pozaczaszkowej często wiąże się jednak z wysokim ryzykiem powikłań. **Opis przypadku:** Przedstawiono przypadek guza typu *schwannoma* umiejscowionego w bocznej części szyi u młodego mężczyzny. Zmiana została początkowo uznana za torbiel łojową. Badanie histopatologiczne wyciętej masy wykazało jednak, że jest to guz typu *schwannoma*. **Wniosek:** Autorzy pragną podkreślić konieczność zwiększonej czujności klinicznej wśród lekarzy prowadzących we wszystkich przypadkach pacjentów zgłaszających się z guzami zlokalizowanymi w bocznej części szyi.

Słowa kluczowe: *schwannoma*, *neurilemmoma*, komórki Schwanna, guzy osłonek nerwowych

INTRODUCTION

Schwannoma is a benign nerve cell tumour also known as neurilemmoma, neurinoma, neurofibroma or spindle-cell tumour. Schwannomas within the head and neck region are common, as nearly 25–45% extracranial schwannomas occur in the head and neck region⁽¹⁾. Approximately 65% of extracranial schwannomas occur in the face, and the remainder 35% in the neck region⁽²⁾. Within the neck, they commonly occur in the lateral region, arising either from cutaneous or muscular branches of the cervical plexus or from the brachial plexus. Medially, they may arise from cranial nerves IX to XII or the sympathetic chain⁽³⁾. The presence of a well-circumscribed lateral neck mass is the most common sign, especially in tumours arising from vagus, lingual and sympathetic nerves.

CASE REPORT

A previously healthy 22-year-old male presented to an otorhinolaryngology clinic with a two-year history of painless, asymptomatic right neck swelling. According to the patient, the right neck mass grew slowly over the years. There was, however, no history of trauma, dental procedures or infection. The patient had no obstructive or constitutional symptoms. He also denied any recurrent nasal or ear symptoms. Horner's sign was negative.

Upon examination, the patient appeared comfortable, febrile and not in respiratory distress. A neck examination revealed a painless, superficial, right lateral neck mass measuring 1 × 1 cm (Fig. 1), cystic, non-pulsatile and mobile in all directions. An intraoral examination along with flexible nasopharyngolaryngoscopy were unremarkable. All cranial nerves were intact. Otoscopy and nasoendoscopy examinations were also normal. A provisional diagnosis of right

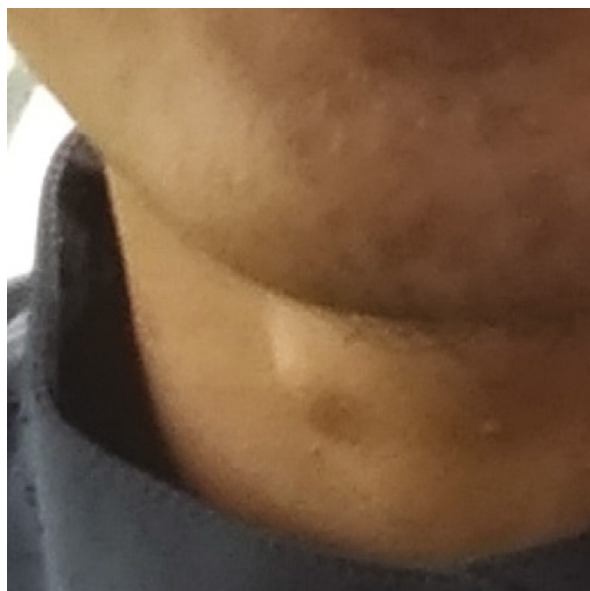

Fig. 1. Superficial, right lateral neck mass measuring 1 × 1 cm

sebaceous cyst was made. The patient was counselled, and excision biopsy of the right neck mass was scheduled.

Intraoperatively, a mass measuring 1 × 1 cm was excised completely without difficulty. Post-operatively, the patient felt well, and was discharged home in a good condition. Histopathological examination of the right neck mass revealed an encapsulated lesion composed of proliferation of spindle cells arranged in hypercellular areas with the presence of Verocay bodies (Antoni A), and hypocellular (Antoni B) areas (Fig. 2). The tumour cells expressed S100 and did not express CD34 or SMA, which is characteristic of schwannoma. No recurrence were noted during the patient's follow-up.

DISCUSSION

Schwannoma was first described in 1908 by Verocay as a pathological entity which was later categorised as neurinoma in 1910. In 1935, Stout proposed that these tumours arose from nerve sheath elements, and termed them as neurilemmomas⁽⁴⁾. Benign and malignant neurogenic tumours make up only a small percentage of all neoplastic tumours in the head and neck region. Benign tumours include neurofibromas, schwannomas, neuromas, neurogenous nevi, and granular cell myoblastomas, whereas malignant tumours include neurogenic sarcomas, malignant schwannomas, and malignant melanomas⁽³⁾. Schwannomas of the head and neck are relatively uncommon compared to neurofibromas, however they share a common precursor, the Schwann cell. Neurofibromas are typically seen in von Recklinghausen's disease, and have a malignant potential^(2,3). Schwannomas, on the other hand, are commonly benign, and may arise from any peripheral, central or autonomic nerve⁽¹⁾. Extracranial schwannomas occur in the head and neck region, most commonly in the lateral part of the neck, as in our patient. Besides that, there are also reported cases of schwannoma located in the parapharyngeal space, retropharyngeal

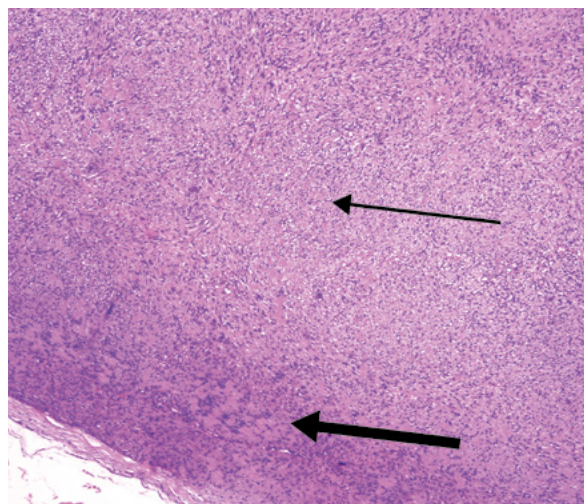


Fig. 2. Magnification ×4 (low power): a well-circumscribed and encapsulated lesion composed of proliferation of tumour spindle cells arranged in hypercellular (Antoni A) (thick arrow) and hypocellular (Antoni B) areas (thin arrow)

space, posterior pharyngeal wall, paranasal sinuses, nasal cavity, scalp, submandibular region, larynx, epiglottis, tongue, infratemporal fossa, cheek, and the oral cavity⁽⁴⁾.

Extracranial head and neck schwannomas usually present insidiously as solitary and well-demarcated lesions. Albeit benign, they may cause secondary symptoms like nasal obstruction, dysphasia, hoarseness, and irradiated pain, depending on the location⁽⁵⁾. Guerrissi reported that 57% of patients presenting with Horner's syndrome had schwannoma arising from the sympathetic chain⁽⁴⁾. Our patient however, did not exhibit any of such symptoms, as the mass was superficially located.

Preoperative diagnosis remains a conundrum for extracranial schwannoma because of its vague presentation. Like most neck masses, fine-needle aspiration cytology (FNAC) is useful in differentiating between benign and malignant soft tissue tumours, but it has low accuracy in the diagnosis of neural tumours⁽¹⁾. Contrast-enhanced computed tomography ought to be done routinely, as some schwannomas are very vascular. In addition, it also clearly demarcates the size and extent of tumour, and the degree of vascularity, and differentiates between benign and malignant lesions.

Definitive diagnosis is possible only via histological analysis of the mass. Histopathologically, there are two types of schwannoma: Antoni A and Antoni B. Type A consists of spindle-shaped cells with long slender fibres forming a parallel arrangement of nuclei, known as palisading of the nuclei around central mass of cytoplasm (Verocay bodies). As for type B, it is degenerative in nature, formed by loosely arranged stroma in which fibres and cells form no distinctive pattern. Schwannomas may also present as a mixture of both types⁽¹⁾, as in our patient. Immunohistochemical studies often show strong positivity for S-100 antibodies, which is typical of schwannoma cells.

The differentials for a lateral neck mass include metastatic or reactive lymphadenopathy, soft tissue neoplasms such as fibroma, leiomyoma, lipoma, paraganglioma, and other neurogenic tumours⁽⁶⁾. The treatment for benign schwannoma consists of total surgical excision. Recurrence has been reported following successful *en bloc* removal.

CONCLUSION

Cervical schwannoma, albeit rare, ought to be considered in the differential diagnosis in all cases involving a lateral neck mass, owing to its morbidity. Scrupulous history-taking and physical examination along with imaging examinations may aid in the diagnosis of this disease entity.

Conflict of interest

The authors do not declare any financial or personal links to other persons or organisations that could adversely affect the content of this publication or claim rights thereto.

References

1. Sharma DK, Sohal BS, Parmar TL et al.: Schwannomas of head and neck and review of literature. *Indian J Otolaryngol Head Neck Surg* 2012; 64: 177–180.
2. Guerrissi JO: Solitary benign schwannomas in major nerve systems of the head and neck. *J Craniofac Surg* 2009; 20: 957–961.
3. Colreavy MP, Lacy PD, Hughes J et al.: Head and neck schwannomas – a 10 year review. *J Laryngol Otol* 2000; 114: 119–124.
4. Conley J, Janecka IP: Neurilemmoma of the head and neck. *Trans Sect Otolaryngol Am Acad Ophthalmol Otolaryngol* 1975; 80: 459–464.
5. Shoss SM, Donovan DT, Alford BR: Tumors of the parapharyngeal space. *Arch Otolaryngol* 1985; 111: 753–757.
6. Setty CMLN: Schwannoma of the cervical vagus nerve: a rare case report. *Int J Otorhinolaryngol Head Neck Surg* 2018; 4: 263–266.