

Received: 21.03.2019

Accepted: 30.07.2019

Published: 30.06.2020

Jeyasakthy Saniasiaya¹, Nik Fariza Husna Nik Hassan^{1,2}, Balwinder Singh Saroop Singh³

Unilateral vocal cord palsy: a never-ending diagnostic dilemma

Jednostronne porażenie strun głosowych: powszechny dylemat diagnostyczny

¹ Department of Otorhinolaryngology – Head and Neck Surgery, School of Medical Sciences, Universiti Sains Malaysia Health Campus, 16150 Kota Bharu, Kelantan, Malaysia

² Audiology and Speech Pathology Programme, School of Health Sciences, Universiti Sains Malaysia Health Campus, 16150 Kota Bharu, Kelantan, Malaysia

³ Department of Otorhinolaryngology – Head and Neck Surgery, Hospital Putrajaya, Pusat Pentadbiran Kerajaan Persekutuan, Presint 7, 62250 Putrajaya, Malaysia

Correspondence: Jeyasakthy Saniasiaya, MD, Department of Otorhinolaryngology – Head and Neck Surgery, School of Medical Sciences, Universiti Sains Malaysia Health Campus, 16150 Kota Bharu, Kelantan, Malaysia, tel.: +6097673000, e-mail: shakthy_18@yahoo.com

Abstract

Aim of the study: We would like to highlight the diagnostic challenges and the management of idiopathic unilateral vocal cord paresis in a young girl. Hoarseness is a common presentation to the otorhinolaryngology department. Nevertheless, this entity keeps many physicians in a quandary, especially when it is secondary to vocal cord paresis without history of head and neck surgery, given the intricate anatomy of the vagus nerve. **Case study:** Herein, we are reporting a case of possible idiopathic unilateral vocal cord paresis in a young girl who presented with one-week history of hoarseness and cough. The patient had a prior surgery for the repair of transposition of the great arteries done in infancy. Flexible endoscopy revealed unilateral vocal cord immobility. Computed tomography revealed no new finding causing vocal cord paresis. The patient was referred to a tertiary centre for injection laryngoplasty. **Conclusion:** Unilateral vocal cord paresis may be caused by a myriad of aetiologies, which adds to the complexity of diagnosing and treating this entity. We would like to highlight various possibilities for the management of this condition.

Keywords: unilateral vocal cord paresis, hoarseness, dysphonia

Streszczenie

Cel badania: W pracy przedstawiono wyzwania diagnostyczne i przebieg leczenia młodej kobiety z idiopatycznym jednostronnym niedowładem strun głosowych. Chrypka jest często zgłaszanym objawem w oddziałach otorhinolaryngologicznych. Objaw ten może być przyczyną problemów diagnostycznych, zwłaszcza jeżeli jest wtórny do niedowładu strun głosowych, a także w przypadku braku dodatniego wywiadu o interwencji chirurgicznej w obrębie głowy i szyi (z uwagi na skomplikowaną anatomię nerwu błędnego). **Opis przypadku:** W artykule opisano przypadek idiopatycznego jednostronnego niedowładu strun głosowych u młodej kobiety, która zgłosiła się do kliniki z utrzymującą się od tygodnia chrypką i kaszlem. W wywiadzie ustalono, że w wieku niemowlęcym pacjentka została poddana korekcji całkowitego przełożenia wielkich pni tętniczych. Na podstawie endoskopii giętkiej stwierdzono jednostronne unieruchomienie strun głosowych. Obrazowanie techniką tomografii komputerowej nie ujawniło żadnych nieprawidłowości, które mogłyby powodować niedowład strun głosowych. Pacjentka została skierowana do ośrodka o trzecim stopniu referencyjności w celu wykonania laryngoplastyki iniekcyjnej. **Wniosek:** Jednostronny niedowład strun głosowych może mieć niezwykle zróżnicowaną etiologię, co dodatkowo komplikuje przebieg diagnostyki i leczenia. Autorzy prezentują różne opcje terapeutyczne, które mogą być wdrożone w leczeniu tego stanu.

Słowa kluczowe: jednostronny niedowład strun głosowych, chrypka, dysfonia

INTRODUCTION

Unilateral vocal cord paresis (UVCP) is a functional disorder which may lead to serious implications in daily activities, especially when it is accompanied by aspiration symptoms. It may be attributed to a lesion in the nucleus ambiguus, its supranuclear tracts, the main trunk of the vagus nerve or the recurrent laryngeal nerve (RLN). RLN lesion or injury has been proposed to be the main factor leading to UVCP. Idiopathic causes of UVCP, albeit common, are often overlooked or undiagnosed, as unilateral vocal cord palsy spontaneously recovers or is compensated by the other vocal cord.

CASE REPORT

A previously healthy 19-year-old Malay girl presented to our clinic with one-week history of hoarseness and cough. According to her report, she noticed that she had difficulty with speaking, and had to make an effort to vocalise, however the hoarseness did not worsen over time. As for the cough, it was non-purulent with no haemoptysis, and was associated with swallowing especially plain water. She denied any choking episodes, dysphagia, odynophagia, weight loss or neck swelling. There were no prior bouts of upper respiratory tract infections, recurrent nasal symptoms or aural symptoms. There was also no history of recent head and neck surgery, neck trauma, foreign body ingestion, inhalational injury or reflux symptoms. There was no recent contact with TB-positive patients, no recent travel or jungle-trekking. The patient is a non-smoker and non-alcoholic. She denied taking any traditional or herbal medications. On further questioning, the patient's parents revealed that the patient had transposition of the great arteries (TGA), and was operated on when she was 1 month old. The surgery, according to the parents, was uneventful and the patient was asymptomatic ever since.

During the review, the patient was sitting comfortably under room air, with no signs of respiratory distress. There was no stridor audible, however her voice was breathy. Intraoral and neck examinations were unremarkable. The lungs were clear. Anterior rhinoscopy and otoscopy were both clear. Flexible nasopharyngolaryngoscopy was performed which revealed immobility of the left hemilarynx, with the left vocal cord in the paramedian position, and mobile right vocal cord with phonation gap (Fig. 1). There was no mucosal lesion or mass seen in the supraglottis, glottis or subglottis. All other cranial nerves were intact, with no other neurological deficits. All blood tests, including complete blood count, renal profile, erythrocyte sedimentation rate, rheumatoid factor, and antinuclear antibodies, were normal. Chest radiography was also normal, with no cardiomegaly, widening of the mediastinum or signs of lung pathology. Consequently, contrast-enhanced computed

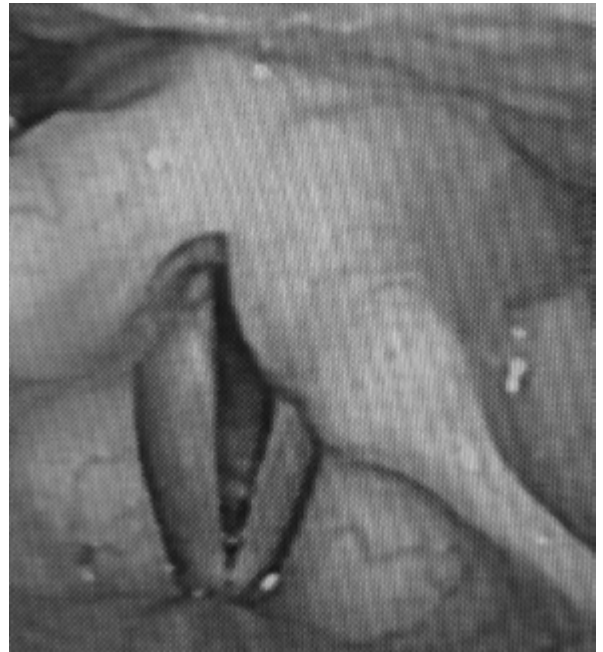


Fig. 1. Flexible nasopharyngolaryngoscopy reveals a paralysed left hemilarynx with the left vocal cord in the paramedian position

tomography (CECT) from the brain to the thorax was done, which revealed the aorta embraced by the right and left pulmonary arteries, with the right ventricle anteriorly located rather than the right atrium which is a typical finding post TGA surgery (Fig. 2). In the light of the patient's presentation and findings, the diagnosis of left vocal cord paresis secondary to an idiopathic cause was made. Another possibility would have been her history of surgical correction of TGA, however it was performed

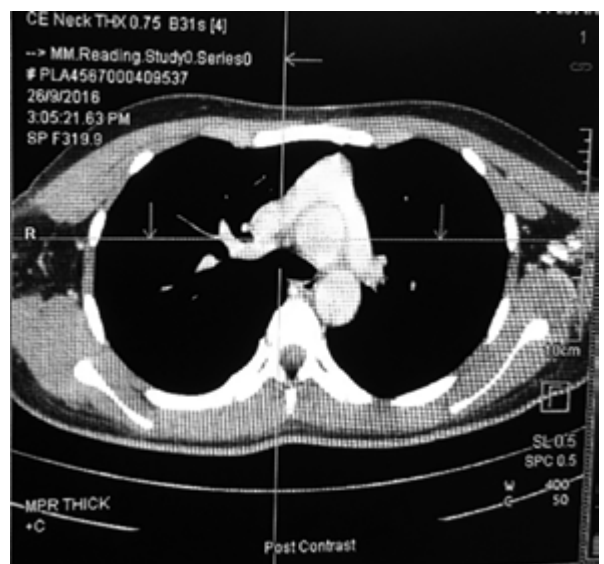


Fig. 2. CECT of the thorax reveals the aorta embraced by the right and left pulmonary arteries, with the right ventricle anteriorly located

19 years earlier. The findings were explained to the patient and her parents, and she was referred to a speech therapist for swallowing and voice rehabilitation. The patient was reviewed again after one week, which revealed that the immobile left vocal cord was still in the paramedian position, with flickering movements, and the phonation gap appeared to be improving from the previous examination. The patient was then advised to undergo a continuous speech therapy follow-up and referred to the laryngology team in a tertiary centre for follow-up and management.

DISCUSSION

UVCP may be secondary to countless causes including neurological conditions such as stroke, motor neuron disease, Guillain-Barré syndrome; neoplastic causes including thyroid, oesophageal, bronchial or in the brainstem; systemic causes including lupus erythematosus, sarcoidosis and amyloidosis; pharmacological causes attributed by vinca alkaloids toxicity; traumatic causes secondary to birth injury, motor vehicle accident; iatrogenic causes following intubation, thyroid surgery, carotid endarterectomy and lastly iatrogenic causes^(1,2). Despite this long list of possible conditions leading to UVCP; postsurgical, idiopathic and neoplastic causes are the most established ones⁽³⁾. Our patient discussed above probably had UVCP of idiopathic origin, as all examinations done revealed normal findings.

Aetiological factors predisposing to UVCP have dramatically changed over the decade. Prior to the 1990s, UVCP was caused by syphilitic aneurysm, tuberculous mediastinal nodes, and post-thyroidectomy⁽⁴⁾. Following the 1990s, non-laryngeal malignancy became the predominant cause. Robust advances in anaesthesia and surgery, have led to a growth in UVCP cases occurring secondary to surgical procedures like anterior cervical spine surgery, carotid endarterectomy, and skull base surgery⁽⁴⁾. Regardless of the rise in the use of computed tomography scanning or other advanced imaging modalities, idiopathic causes of UVCP remain eminent to date⁽⁴⁾, and should not be overlooked.

As for the predominant side of UCVP, left-sided vocal cord palsy is more common than right-side⁽⁵⁾ owing to the length of the left RLN. In general, right RLN is 5–6 cm from its root at the level of the brachiocephalic artery to the cricothyroid joint. The left RLN, however, has a longer course which is 12 cm from its origin at the aortic arch to the cricothyroid joint owing to its predominance in UVCP⁽⁶⁾. Despite that, there are studies that claim that right-sided is twice as common as left-sided UVCP⁽⁷⁾.

As for the presenting complaints, notable ones include hoarseness, stridor, shortness of breath, and aspirating symptoms like cough. Despite that, up to 40% of people with UVCP may remain asymptomatic, which leads to a delay in diagnosis⁽⁸⁾. Our patient presented with hoarseness and cough for a short duration of one-week.

Patients presenting with hoarseness require thorough history taking and physical examination. UVCP is usually diagnosed by performing flexible nasopharyngolaryngoscopy (FNL) in the clinical setting. In addition to providing information about cord palsy, it allows an assessment of the presence of phonation gap, a mass or other abnormalities in the supraglottis, glottis or subglottis, contributing to this pathology. In our patient, FNL revealed the left vocal cord in the paramedian position, with minimal phonation gap and normal-looking laryngeal mucosa.

Imaging should be performed to identify the factor leading to UVCP, including simple chest radiography to look for any mediastinal widening or bronchogenic mass. Computed tomography (CT) scanning allows the identification of pathologies from the brain down to the thorax. Typical findings of UVCP in a CT scan of the neck can be seen in the axial cut which shows: ipsilateral pyriform sinus dilatation, medial rotation and thickening of the aryepiglottic fold, and ipsilateral laryngeal ventricle dilatation⁽⁹⁾. Based on a study by Chin et al. in 2003, two out of these three CT findings were noted amongst their patients⁽¹⁰⁾. Other diagnostic procedures or tools which may depict the aetiology of this entity include direct laryngoscopy under general anaesthesia, magnetic resonance imaging, laryngeal ultrasound⁽¹¹⁾, serological assays including tests for rheumatoid factor, erythrocyte sedimentation rate, Lyme titres along with antinuclear antibodies, and finally laryngeal electromyography which serves more as a prognostic indicator⁽¹²⁾. Misono and Merati suggest cross-sectional imaging along with laryngeal electromyography as a tool for the diagnosis and a prognostic predictor, respectively⁽³⁾.

As for the management of UVCP, it should be tailored to the patient's complaints as well as the aetiological causes. There is no need for hasty surgical interventions, as late spontaneous recovery is possible⁽¹³⁾. Idiopathic causes of laryngeal paralysis is mostly unilateral, with spontaneous recovery seen in 71% of cases⁽¹¹⁾. The main aim of treatment should be centred on improving the patient's voice and preventing aspiration. As for our patient, taking into consideration the fact that her symptoms are improving, watchful waiting may be possible. In the interim, rehabilitation with a speech pathologist should be continued. Voice therapy alone as a sole treatment is not sufficient for patients with UVCP⁽³⁾. If surgery is deemed necessary, there are multiple options, as the surgical armamentarium of modalities for the treatment of UVCP has continued to expand over the years, and all of them are centred on medialising the vocal fold. Injection medialisation and medialisation thyroplasty were found to have similar initial outcomes, however the long-term outcome favours the medialisation thyroplasty⁽³⁾. Similarly, medialisation thyroplasty and laryngeal reinnervation were found to have a good voice outcome⁽³⁾. The prognosis of laryngeal paralysis as a whole depends on its aetiological or associated factors. Spontaneous recovery occurs within 6 months, though there have been cases in which recovery was seen after 5 years. Laryngeal paralysis

secondary to a peripheral cause has been associated with better outcomes than the central cause⁽¹³⁾.

CONCLUSION

As a whole, despite its perplexing nature, the management of UVCP ought to be taken seriously, keeping in mind its potentially devastating complications, notably aspiration. We suggest that all patients with UVCP should be subject to regular follow-up despite the self-limiting nature of this entity.

Conflict of interest

The authors do not report any financial or personal affiliations to persons or organisations that could adversely affect the content of or claim to have rights to this publication.

References

1. Yuskovitch A, Enepekides DJ, Hier MP et al.: Guillain-Barré syndrome presenting as bilateral vocal cord paralysis. *Otolaryngol Head Neck Surg* 2000; 122: 269–270.
2. Havas T, Lowinger D, Priestley J: Unilateral vocal fold paralysis: causes, options and outcomes. *Aust N Z J Surg* 1999; 69: 509–513.
3. Misono S, Merati AL: Evidence-based practice: evaluation and management of unilateral vocal fold paralysis. *Otolaryngol Clin North Am* 2012; 45: 1083–1108.
4. Sulica L, Cultrara A, Blitzer A: Vocal fold paralysis: causes, outcomes, and clinical aspects. In: Sulica L, Blitzer A (eds.): *Vocal Fold Paralysis*. Springer, Heidelberg 2006: 33–54.
5. Daya H, Hosni A, Bejar-Solar I et al.: Pediatric vocal cord paralysis: a long-term retrospective study. *Arch Otolaryngol Head Neck Surg* 2000; 126: 21–25.
6. Delorme S, Knopp MV, Kauczor HU et al.: [Recurrence paralysis: computed tomographic analysis of intrathoracic findings]. *Radiologie* 1992; 32: 430–435.
7. Thirlwall AS: Ortner's syndrome: a centenary review of unilateral recurrent laryngeal nerve palsy secondary to cardiothoracic disease. *J Laryngol Otol* 1997; 111: 869–871.
8. Yumoto E, Minoda R, Hyodo M et al.: Causes of recurrent laryngeal nerve paralysis. *Auris Nasus Larynx* 2002; 29: 41–45.
9. Paquette CM, Manos DC, Psooy BJ: Unilateral vocal cord paralysis: a review of CT findings, mediastinal causes, and the course of the recurrent laryngeal nerves. *Radiographics* 2012; 32: 721–740.
10. Chin SC, Edelstein S, Chen CY et al.: Using CT to localize side and level of vocal cord paralysis. *AJR Am J Roentgenol* 2003; 180: 1165–1170.
11. Pavithran J, Menon JR: Unilateral vocal cord palsy: an etiopathological study. *IJOPL* 2011; 1: 5–10.
12. Virk JS, Majithia A, Lingam RK et al.: Cervical osteophytes causing vocal fold paralysis: case report and literature review. *J Laryngol Otol* 2012; 126: 963–965.
13. Tiago RSL, Patrocinio SJ, dos Anjos PSF et al.: [Vocal fold paralysis in children: diagnostic and management from a case report]. *Braz J Otorhinolaryngol* 2005; 71: 382–385.