

Received: 20.05.2019

Accepted: 30.07.2019

Published: 30.06.2020

Jeyasakthy Saniasiaya¹, Norhafiza Mat Lazim¹, Salma Win Mar²

Calcified triticeal cartilage: a red herring

Zwapnienie chrząstki ziarnowatej jako przyczyna błędnych tropów w diagnostyce

¹ Department of Otorhinolaryngology – Head and Neck Surgery, School of Medical Sciences, Universiti Sains Malaysia Health Campus, 16150 Kota Bharu, Kelantan, Malaysia

² Department of Radiology, School of Medical Sciences, Universiti Sains Malaysia Health Campus, 16150 Kota Bharu, Kelantan, Malaysia

Correspondence: Jeyasakthy Saniasiaya, MD, Department of Otorhinolaryngology – Head and Neck Surgery, School of Medical Sciences, Universiti Sains Malaysia Health Campus, 16150 Kota Bharu, Kelantan, Malaysia, tel.: +6097673000, e-mail: shakthy_18@yahoo.com

Abstract

Aim: To illustrate the importance of awareness of calcified triticeal cartilage which may mimic a foreign body. Unintentional foreign body ingestion, albeit common, still remains a quandary to many physicians, particularly otorhinolaryngologists. **Case study:** Herein, we are reporting the case of a middle-aged female who presented to us post ingestion of a duck bone. The patient had no obstructive symptoms. A lateral soft tissue neck radiograph revealed an opaque foreign body at the level of the fourth and fifth cervical vertebrae, which was removed under general anaesthesia. Repeated lateral neck radiography revealed a foreign body which turned out to be calcified triticeal cartilage. **Conclusion:** Familiarity with the problem of calcified laryngeal cartilage is imperative amongst clinicians so as to prevent misdiagnosis which may even jeopardize the patient's life.

Keywords: calcification, laryngeal cartilage, foreign body ingestion

Streszczenie

Cel: Celem pracy jest zwrócenie uwagi na zwapnienie chrząstki ziarnowatej, którego obraz może przypominać obecność ciała obcego. Niezamierzone połknięcie i uwięźnięcie ciała obcego, choć występuje powszechnie, nadal sprawia trudności wielu lekarzom, a zwłaszcza otorynolaryngologom. **Opis przypadku:** W pracy przedstawiono przypadek kobiety w średnim wieku, która zgłosiła się do kliniki po połknięciu kości z kaczki. U pacjentki nie występowały objawy niedrożności. W badaniu rentgenowskim tkanek miękkich szyi w projekcji bocznej potwierdzono obecność nieprzezroczystego ciała obcego na poziomie czwartego i piątego kręgu szyjnego, które usunięto w znieczuleniu ogólnym. Kontrolne badanie radiologiczne szyi w projekcji bocznej ponownie sugerowało obecność ciała obcego. Ostatecznie okazało się, że obraz radiologiczny odpowiada zwapnieniu chrząstki ziarnowatej. **Wniosek:** Znajomość obrazu diagnostycznego zwapnienia chrząstki ziarnowatej wśród klinicystów pozwala zapobiec błędnym rozpoznaniom, które w skrajnych przypadkach mogą zagrażać życiu pacjenta.

Słowa kluczowe: zwapnienie, chrząstka krtaniowa, połknięcie ciała obcego

INTRODUCTION

Calcification of the airway cartilage seen on plain neck radiographs becomes a dilemma to many physicians, as it mimics a foreign body. This mostly involves the calcification process of the posterior part of the thyroid cartilage, the posterior part of the cricoid cartilage and the arytenoid cartilage⁽¹⁾, which is a part of the aging process. Albeit a myriad of cases have been reported on calcified laryngeal cartilage feigning a foreign body, to our knowledge this is the second reported case involving calcified triticeal cartilage.

CASE REPORT

A previously healthy 43-year-old Malay female was referred to our centre with a two-day history of foreign body ingestion. According to the patient, she accidentally swallowed a piece of duck bone while having dinner, and experienced odynophagia ever since. She was only able to take a soft diet in minimal amounts due to a bothersome pricking sensation. Apart from that, there was no accompanying shortness of breath, stridor or hoarseness. She denied any fever, neck swelling, haemoptysis, chest pain or interscapular pain. Clinically, the patient was comfortable under room air, not septic-looking, with no signs of respiratory distress. An intraoral examination showed no evidence of a foreign body or pooling of saliva. Nasal and aural examinations were both unremarkable. A neck examination demonstrated no swelling or emphysema, and laryngeal crepitus was present. The patient's systemic examination and blood parameters were also within the normal limits. However, there was slight pain over the left side of the neck upon turning the head to the left side.

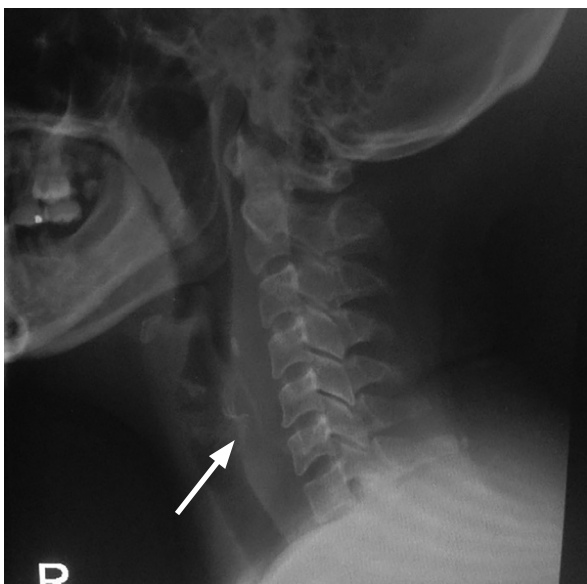


Fig. 1. Opaque foreign body seen at the level of the 4th–5th cervical vertebrae (arrow pointing towards the foreign body)




Fig. 2. Removed duck bone measuring 2.5 × 0.5 cm

70-degree laryngoscopy was done in our clinic, which demonstrated pooling of saliva bilaterally over the pyriform fossa, with mildly oedematous left arytenoid. Bilateral vocal folds were symmetrical and mobile, with a patent airway. However, no signs of a foreign body were visualised. A lateral soft tissue neck (STN) radiograph revealed a vertically placed opaque foreign body at the level of the fourth and fifth cervical vertebrae, and loss of cervical lordosis with no evidence of widened prevertebral soft tissue (Fig. 1). The patient's chest radiograph was unremarkable. Hence, after the patient's consent was obtained, she underwent direct laryngoscopy with esophagoscopy and removal of the foreign body under general anaesthesia. Intraoperatively, the foreign body was seen lying longitudinally at the level of the cricopharynx – 15 cm from the level of the upper incisor, measuring 2.5 × 0.5 cm (Fig. 2), and was removed without difficulty. However, during the removal of the foreign body, a mucosal tear was seen. Oesophagoscopy was then performed up to the level of

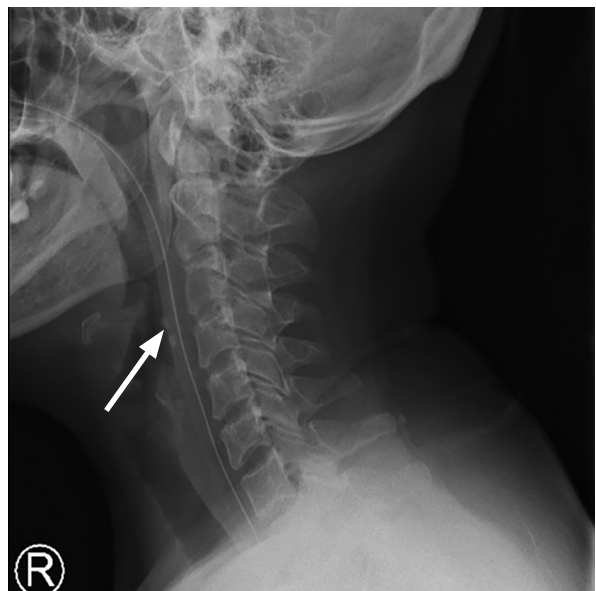


Fig. 3. Triticeal cartilage masquerading as a foreign body

25 cm from the upper incisor, showing no intraluminal foreign body.

Postoperatively, the patient was comfortable, with no signs of mediastinitis or emphysema. She was kept nil by mouth, and was started on Ryle's tube feeding. To our surprise, however, a repeat lateral STN radiograph showed evidence of retained foreign body (Fig. 3).

Consequently, a discussion was held with a radiologist regarding the necessity of a computed tomography scan of the neck to rule out retained foreign body, as a mucosal tear was visible intraoperatively. However, the radiologist concluded that the opaque-looking foreign body was in fact calcified triticeal cartilage. The patient was allowed orally, and was discharged home on the subsequent day, with a one-week course of oral amoxicillin/clavulanic acid. During her follow-up, the patient was noted to be completely asymptomatic and well.

DISCUSSION

The triticeal cartilage derives its name from the Latin word *triticeous* which means "appearing like a grain of wheat"⁽²⁾. To date, no functional or pathological significance of this cartilage has been documented, and it has received little attention in the literature. The triticeal cartilage is a small cartilaginous nodule located between the superior horn of the thyroid cartilage and the greater horn of the hyoid cartilage within the lateral thyrohyoid ligament⁽³⁾.

Although the terms "calcification" and "ossification" are used interchangeably, the calcification process takes place prior to ossification when cartilage is turned into bone⁽⁴⁾. Similar to other hyaline-derived laryngeal cartilage types including the thyroid, cricoid and part of the arytenoid, the triticeal cartilage is hyaline in nature, and thus susceptible to the calcification process. To date, only one case has been reported on the ossified triticeal cartilage causing dysphagia⁽²⁾.

Plain radiography plays a crucial role aiding in the diagnosis of the foreign body, especially when the clinical examination is unremarkable. The type of radiograph is usually selected based on the patient's symptoms. For instance, if odynophagia is appreciated above the sternal level, it usually warrants a plain lateral neck radiograph – as in our patient. It should, however, be borne in mind that lateral neck radiography has its own limitations and pitfalls

in the presence of false positive and false negative findings. In our case, the presence of calcified triticeal cartilage gave rise to a false positive appearance of retained foreign body. Complete reliance on lateral neck radiography should also be avoided, as a negative finding may be secondary to a radiolucent foreign body which many physicians may overlook⁽⁵⁾.

Symptomatic patients with a positive history, and negative laryngoscopy and neck radiograph should be subjected to direct laryngoscopy and oesophagoscopy under general anaesthesia to justify the absence of the foreign body, and avoid devastating complications of missed or retained foreign body including airway obstruction, oesophageal perforation, mediastinitis and fistulisation⁽⁵⁾. Computed tomography of the neck is another expedient option when in doubt about the presence, location or retained foreign body.

CONCLUSION

Apart from thorough and scrupulous history taking and clinical examination, awareness and familiarity with the problem of calcified laryngeal cartilage is imperative amongst clinicians so as to prevent misdiagnosis which may even jeopardize the patient's life.

Conflict of interest

The authors do not report any financial or personal affiliations to persons or organisations that could adversely affect the content of or claim to have rights to this publication.

References

1. Divya GM, Muhammad H, Ramachandran KC et al.: Vertical cricoid lamina ossification: a rare pitfall in the diagnosis of extraluminal foreign body. *Int J Head Neck Surg* 2014; 5: 91–93.
2. Alsarraf R, Mathison S, Futran N: Symptomatic presentation of an enlarged, ossified triticeal cartilage. *Am J Otolaryngol* 1998; 19: 339–341.
3. Sakamoto Y: Gross anatomical observations of attachments of the middle pharyngeal constrictor. *Clin Anat* 2014; 27: 603–609.
4. Mupparapu M, Vuppalapati A: Ossification of laryngeal cartilages on lateral cephalometric radiographs. *Angle Orthod* 2005; 75: 196–201.
5. Saniasiaya J, Mohamad I: Missed hypopharyngeal foreign body: a case report. *Egyptian Journal of Ear, Nose, Throat and Allied Sciences* 2016; 17: 47–48.