

Farah Dayana Zahedi¹, Lian See Sandie Ewe², Salina Husain¹, Kwee Chu Keah³

Ostre inwazyjne grzybicze zapalenie błony śluzowej nosa i zatok z rozsianą fuzariozą naśladującą ospę wietrzną u dziecka z obniżoną odpornością

Acute invasive fungal rhinosinusitis with disseminated fusariosis mimicking chicken pox in an immunocompromised child

¹ Department of Otorhinolaryngology, UKM Medical Center, Kuala Lumpur, Malaysia

² Department of Otorhinolaryngology, Hospital Sultan Ismail, Johor Bahru, Johor, Malaysia

³ Department of Pathology, Hospital Pulau Pinang, Pulau Pinang, Malaysia

Adres do korespondencji: Farah Dayana Zahedi, Department of Otorhinolaryngology, UKM Medical Center, Jalan Yaacob Latif, Bandar Tun Razak, 56000, Cheras, Kuala Lumpur, Malaysia, tel.: +60124248205, e-mail: anna_firra82@yahoo.com.au

Streszczenie

Ostre inwazyjne grzybicze zapalenie błony śluzowej nosa i zatok jest rzadkim schorzeniem nosa i zatok przynosowych, najczęściej występującym u pacjentów z obniżoną odpornością. W praktyce laryngologicznej przypadki ostrego inwazyjnego grzybiczego zapalenia błony śluzowej nosa z rozsianą fuzariozą przypominającą infekcję wywołaną przez wirus *Varicella zoster* zdarzają się niezwykle rzadko. U osób z obniżoną odpornością zachorowalność i śmiertelność utrzymują się na wysokim poziomie i zależą od wdrożonego postępowania – kluczową rolę odgrywają odpowiednio przeprowadzone badania i leczenie. W artykule opisano przypadek ostrego inwazyjnego grzybiczego zapalenia błony śluzowej nosa i zatok z rozsianą fuzariozą u dziecka ze zmianami skórnymi przypominającymi wysypkę wywołaną przez wirus *Varicella zoster*, bólem i obecnością strupa w obrębie jamy nosowej. Podkreślono istotną rolę lekarza laryngologa we wczesnym rozpoznaniu i właściwym leczeniu.

Słowa kluczowe: fuzarioza, grzyby, pacjent z obniżoną odpornością, jama nosowa, ospa

Abstract

Acute invasive fungal rhinosinusitis is a rare sinonasal infection. It usually occurs in immunocompromised patients. The presentation of acute invasive fungal rhinosinusitis with disseminated fusariosis mimicking varicella zoster cutaneous lesion is extremely rare in otorhinolaryngology practice. The morbidity and mortality rates in immunocompromised patient are high and determined by proper management of the disease. Therefore, appropriate investigation and management are very important. We describe a case of acute invasive fungal rhinosinusitis with disseminated fusariosis in a child presenting with cutaneous lesions mimicking varicella zoster associated with nasal pain and eschar. This report also emphasised the important role of an otorhinolaryngologist in the early diagnosis and management of acute invasive fungal rhinosinusitis.

Keywords: fusariosis, fungi, immunocompromised patient, nose, chicken pox

INTRODUCTION

Invasive fungal infections are the major cause of mortality from infection in immunocompromised patients with haematological diseases. Among immunocompromised patients, fusariosis represents the second most common cause of fungal infection after aspergillosis⁽¹⁾. We describe a case of disseminated fusariosis in an immunocompromised child with negative blood cultures, presenting initially with persistent fever with varicella zoster-like cutaneous lesions and nasal pain. High index of clinical suspicion, proper nasal tissue sampling coupled with the role of potassium hydroxide (KOH) microscopy was instrumental to the early confirmation of invasive fungal infection in this child.

CASE REPORT

A 9-year-old girl in the paediatric haemato-oncology unit, who initially presented with an episode of hemophagocytic lymphohistiocytosis (HLH), developed new-onset fever with cutaneous lesions started off as a solitary macular rash over her anterior chest with numerous maculopapular lesions appearing over the chest, abdomen and both lower limbs over the next four days, most of which were distributed over the right lower limb. The lesions subsequently became vesicular before developing a necrotic centre (Fig. 1A–C). She was commenced on IV acyclovir and her antibiotics were upgraded from IV ceftriaxone to IV meropenem. Prior to the above presentation, she had been having persistent fever with pancytopenia for the past 10 days and hepatosplenomegaly. Blood cultures were consistently negative. She had been on high dose dexamethasone (a total of 56 mg over 5 days) as part of her treatment for HLH but the precipitating factor for her HLH had yet to be identified. In addition, she had been experiencing unilateral left nasal pain with dryness for the last 2 days.

The child was referred to the otolaryngology department for evaluation of her unilateral nasal pain since it had resulted in the child's refusal to comply with a nasal oxygen mask.

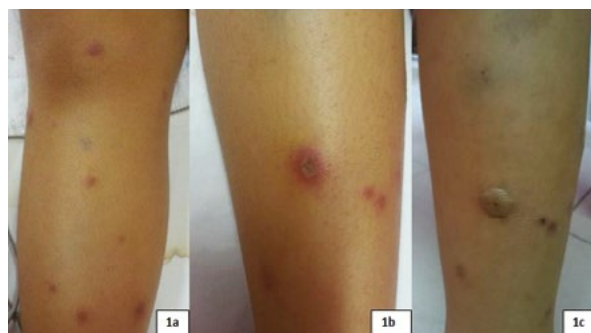


Fig. 1. A–C. Progression of the cutaneous lesions over the right lower limb. It started off as maculopapular lesions, initially mistaken as varicella zoster infection, then it became vesicular before developing a necrotic centre

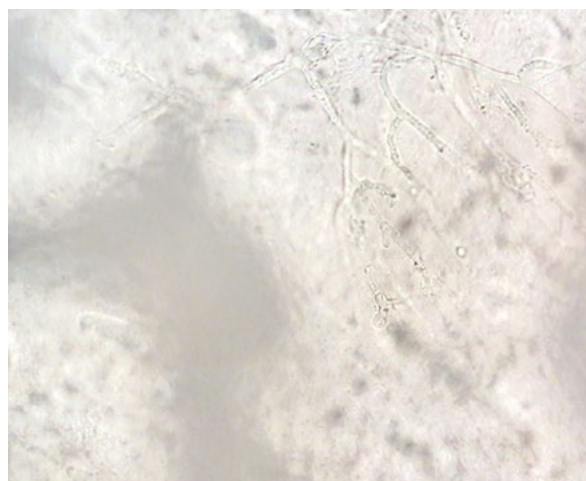


Fig. 2. Morphology of the fungal hyphae identified under light microscopy was that of aseptate fungal hyphae with branching patterns

There were no symptoms of nasal obstruction, purulent rhinorrhoea, headache, facial pain or visual disturbances. On examination, the child was lethargic looking with gross pallor and icterus. There was no obvious facial or periorbital swelling or evidence of skin discolouration over the nasal dorsum. Cold spatula test was negative on the left side. Anterior rhinoscopy revealed the presence of extensive black eschar with the involvement of the septum, resulting in total occlusion of the left nasal cavity. There was minimal eschar over the right middle turbinate. Cotton-like material with minimal black eschar was seen over the anterior septum, but otherwise no obvious perforation was seen. Nasal tissue samples were sent for KOH microscopy, histopathological examination (HPE) and fungal culture. Morphology of the fungal hyphae identified under light microscopy by the microbiologist was that of aseptate fungal hyphae with branching patterns (Fig. 2). The fungus was preliminarily identified as *Aspergillus* species. Intravenous amphotericin-B was initiated based on the positive KOH microscopy findings. HPE confirmed angioinvasion of nasal mucosa by fungi and fungal cultures subsequently came back a week later, with the fungi identified as *Fusarium solani*. This confirmed the diagnosis of acute invasive fungal rhinosinusitis (AIFRS). Radiologically, the disease was confined to the sinonasal region. The cutaneous lesions were also biopsied by a dermatology team. Culture from the skin scrapings also grew *Fusarium solani*. The diagnosis was therefore revised to disseminated fusariosis.

The child's clinical improvement was apparent once systemic antifungal was started. Once her acute liver failure resolved, she underwent surgery – examination of the nose with debridement under anaesthesia. Intraoperatively, both nasal cavities were filled with crusting and necrotic debris. There was a 2 × 2 cm septal perforation with necrosis of the surrounding cartilage and mucosa. The right inferior and middle turbinates were atrophic. No pus was seen in both osteomeatal complexes. HPE confirmed angioinvasion by

fungi with no evidence of concomitant malignancy. Intraoperative fungal culture once again identified the fungi as *Fusarium solani*. She completed 6 weeks of voriconazole. Endoscopic surveillance showed no evidence of recurrence after 30 days. At present, she is still undergoing chemotherapy for her newly diagnosed acute lymphoblastic leukaemia, which turned out to be the precipitating factor for her episode of HLH.

DISCUSSION

AIFRS is a rare entity, seen almost exclusively in immunocompromised patients. AIFRS most commonly presents with fever, nasal obstruction, headache and purulent rhinorrhoea with nasal crusting. The nasal symptoms may be either unilateral or bilateral and, in extensive cases with extranasal involvement, patients may present with progressive skin discolouration over the nasal dorsum, palatal ulcer, visual disturbances or symptoms of intracranial extension^(2,3). Our patient's clinical presentation was atypical of AIFRS – presenting with unexplained fever with varicella zoster-like cutaneous lesions followed by unilateral nasal pain and dryness on wearing a face oxygen mask.

The child's presentation of persistent fever with pancytopenia, hepatosplenomegaly and subsequent development of varicella zoster-like cutaneous lesions followed by unilateral nasal pain and nasal dryness posed a diagnostic dilemma. It was initially believed that the cutaneous lesions could be a part of HLH since as many as 65% of patients have cutaneous involvement. The cutaneous lesions in HLH are variable, ranging from generalised purpuric macules and papules, purpuric morbilliform eruptions to erythroderma. HLH is an uncommon systemic inflammatory response syndrome that is commonly triggered by infection and can occur in association with underlying neoplastic, infectious, autoimmune or hereditary diseases⁽⁴⁾. However, despite commencement of high-dose dexamethasone for the episode of HLH, the child continued to clinically deteriorate. The possibility of varicella zoster infection was considered since the cutaneous lesions mimicked varicella zoster infection, and the unilateral nasal pain was assumed to be due to nasal crusting secondary to varicella zoster infection.

The child's cutaneous lesions continued to progress after four days prompting referrals to the otolaryngology and dermatology departments since varicella zoster infections do not usually progress after four days of onset. On anterior rhinoscopy, we found bilateral intranasal eschar tissue involving the septum. Black eschar results from vascular thrombosis and tissue necrosis. In a paediatric patient, the finding of unilateral black intranasal eschar tissue is seen more commonly in association with button battery injury. The peak incidence of foreign body impaction in the nasal cavity is between the ages of 2–5 years old. Our patient was older than the usual presenting age group and without recent history of button battery insertion into the nose;

therefore, it was unlikely that the symptoms were secondary to button battery injury. Moreover, it is highly unusual for button battery injury to present with bilateral intranasal eschar tissue. The presence of intranasal black eschar in an immunocompromised patient was alarming since black eschar is a late finding in AIFRS.

There was already extension of AIFRS to the septum, which is an indicator of poor prognosis. AIFRS usually begins at the middle turbinate, in the lateral wall of the nasal cavity. Once AIFRS has extended to the nasal septum, the mortality rate doubles from 33% to 67%. Important etiological agents of AIFRS include *Aspergillus*, *Mucor* and *Fusarium* sp.⁽⁵⁾. Early confirmation of the diagnosis of AIFRS is crucial for the initiation of therapy. The mainstay of treatment is systemic antifungal and surgical debridement. However, surgical debridement is invasive, while systemic antifungal therapy is not devoid of adverse effects. Amphotericin B, for instance, may aggravate the child's liver failure, whereas voriconazole may result in visual disturbances.

Diagnostic confirmation of AIFRS is based on a positive fungal culture and evidence of mucosal tissue invasion via HPE. Fungal cultures can be difficult and time-consuming to grow. In our hospital facility, a positive fungal culture may take about 1–3 weeks for species identification. It needs to be emphasised that when collecting clinical specimens for fungal culture, only tissue samples rather than nasal swab samples should be sent. This is because a nasal swab reflects recent air sampling rather than evidence of fungal disease. The HPE of the nasal tissue of our patient was released after 3 days, and confirmed mucosal tissue invasion and the presence of fungal bodies. Species identification, while possible in selected cases via HPE, was difficult in our case due to the presence of extensive tissue necrosis.

Therefore, microscopic examination of nasal tissue by KOH mount, which can be performed immediately by a microbiologist, would be a useful adjunct. KOH digests proteinaceous material and debris, allowing visualisation of the fungal hyphae under light microscopy. This method is inexpensive and permits a rapid diagnosis of fungal infection based on the morphological examination of the fungal hyphae. Important etiological agents of AIFRS include *Aspergillus*, *Mucor* and *Fusarium*. On microscopy, one can comment on the absence or presence of septations as well as appreciate the branching patterns. *Mucor* sp. has non-septated hyphae, whereas both *Aspergillus* and *Fusarium* are septated fungi with differing branching patterns. *Aspergillus* species demonstrate acute branching pattern, while *Fusarium* species demonstrate right angle branching. Definitive identification of these fungi still requires culture as branching patterns may not be easily identified in practice, and hence *Fusarium* may be misdiagnosed as *Aspergillus* on KOH microscopy, as in our case. Nevertheless, the presence of cutaneous lesions is a useful supportive diagnostic clue since 70% of patients with fusariosis have cutaneous involvement. In contrast, cutaneous involvement is rare in infections caused by other opportunistic fungi, such as *Aspergillus* and *Candida* (<10%)⁽⁶⁾.

CONCLUSION

Unilateral nasal pain may be the sole nasal symptom in AIFRS, as demonstrated in our case. Although an uncommon presentation, any immunocompromised child with persistent fever and nasal pain, with or without cutaneous lesions, should be referred to an otolaryngology team to rule out AIFRS. When associated with progressive varicella zoster-like cutaneous lesions, fusarium is the most likely causative agent of AIFRS. We would like to advocate the routine use of KOH microscopy for early confirmation of fungal infection via identification of fungal hyphae in order to facilitate the initiation of treatment for improved outcomes. Tissue samples should be sent with adequate adjacent viable tissue rather than necrotic tissue or nasal swab when sending for fungal culture.

Konflikt interesów

The authors declare that they have no conflict of interest.

Piśmiennictwo

1. Nucci M, Anaissie E: *Fusarium* infections in immunocompromised patients. *Clin Microbiol Rev* 2007; 20: 695–704.
2. Gillespie MB, O'Malley BW Jr, Francis HW: An approach to fulminant invasive fungal rhinosinusitis in the immunocompromised host. *Arch Otolaryngol Head Neck Surg* 1998; 124: 520–526.
3. Idris N, Lim LHY: Nasal eschar: a warning sign of potentially fatal invasive fungal sinusitis in immunocompromised children. *J Pediatr Hematol Oncol* 2012; 34: e134–e136.
4. Rosado FGN, Kim AS: Hemophagocytic lymphohistiocytosis: an update on diagnosis and pathogenesis. *Am J Clin Pathol* 2013; 139: 713–727.
5. Valera FCP, do Lago T, Tamashiro E et al.: Prognosis of acute invasive fungal rhinosinusitis related to underlying disease. *Int J Infect Dis* 2011; 15: e841–e844.
6. Nucci M, Anaissie E: Cutaneous infection by *Fusarium* species in healthy and immunocompromised hosts: implications for diagnosis and management. *Clin Infect Dis* 2002; 35: 909–920.